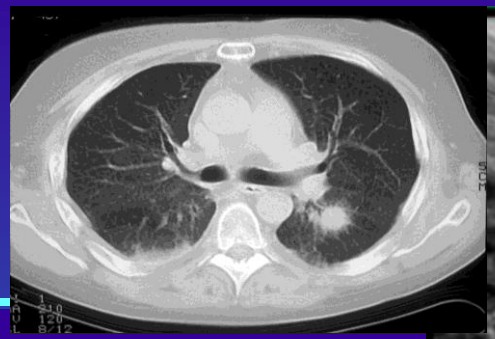

CHU Dinant Godinne

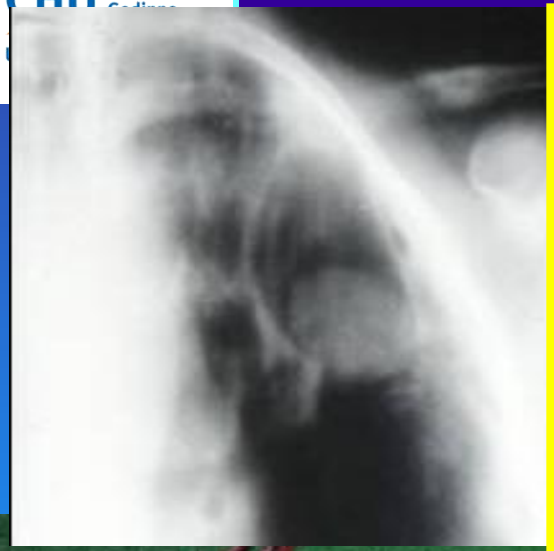

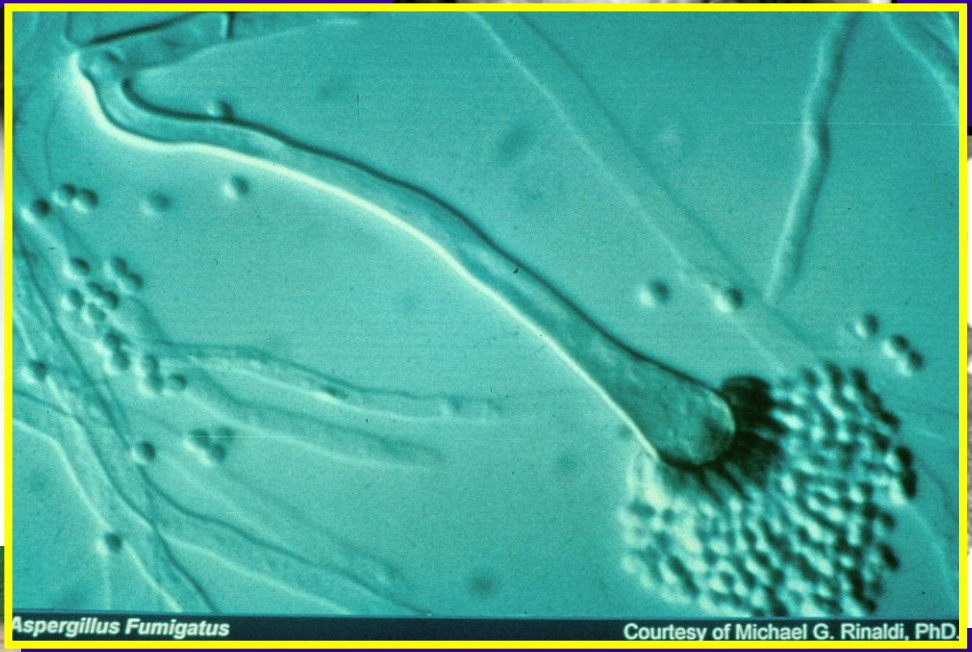

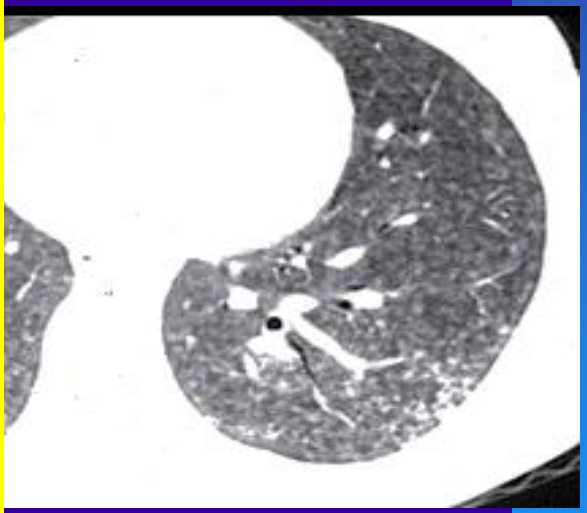



PATHOLOGIES ASPERGILLAIRES:

Aspects cliniques

Docteur P. Bulpa
Service des Soins Intensifs
Cliniques Universitaires de Mont-Godinne

Remerciements: Pr/Dr Delos, Fervaille

PATHOLOGIES ASPERGILLAIRES PULMONAIRES:

Aspects cliniques

Docteur P. Bulpa
Service des Soins Intensifs
Cliniques Universitaires de Mont-Godinne

Remerciements: Pr/Dr Delos, Fervaille

INTRODUCTION

ASPERGILLUS

- Multiples espèces
  - Aspergillus fumigatus: 90% des cas
  - Suivi par l'A. flavus; A. niger; A. terreus et A. nidulans

- Organisme ubiquitaire, surtout dans les produits en décomposition, également dans les plantes, les épices et le poivre, lors de toute destruction de bâtiment.

INTRODUCTION

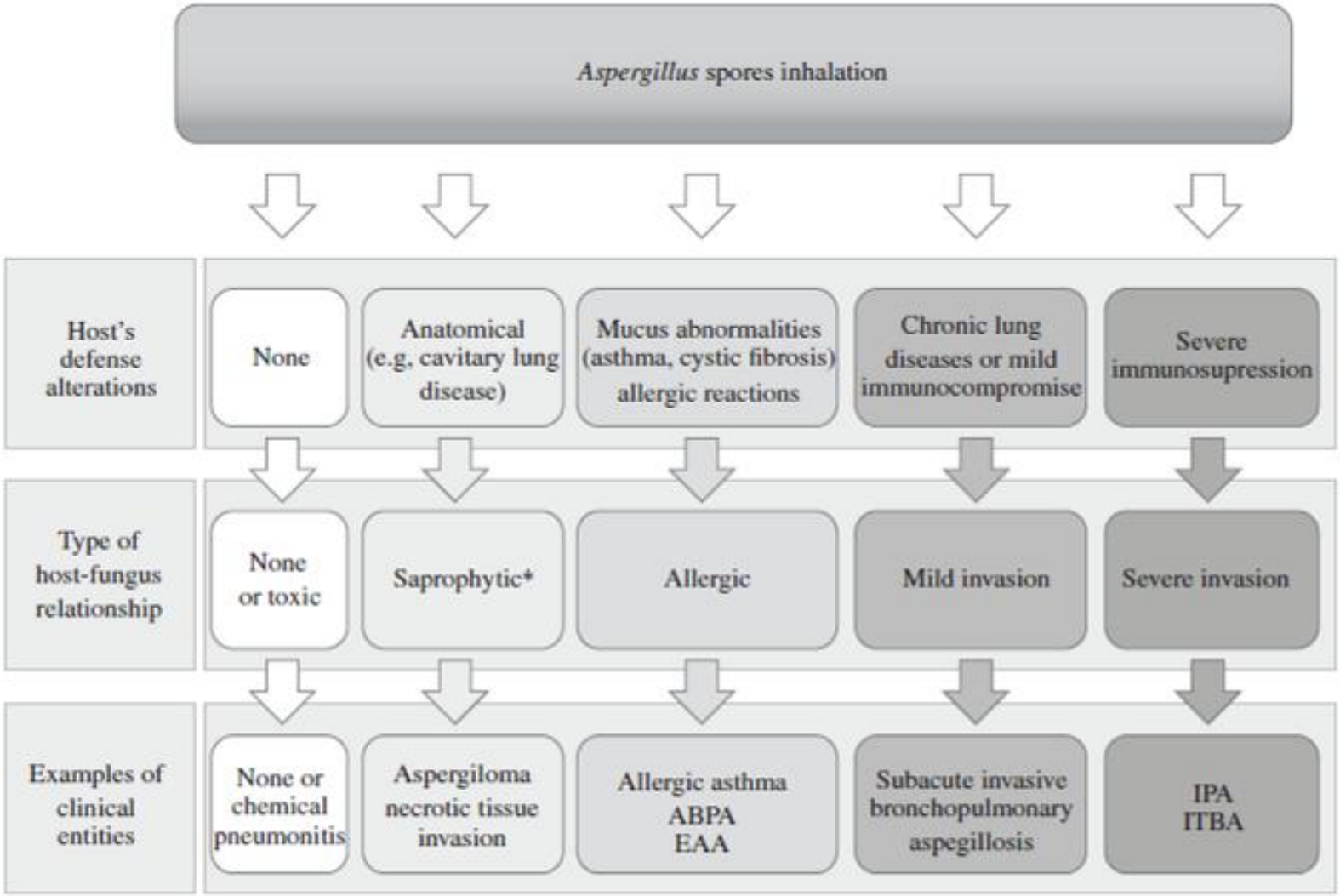

L'aspergillose pulmonaire non invasive



CHU Dinant Godinne
UCL NAMUR

Patient immunocompétent

- **Colonisation simple**

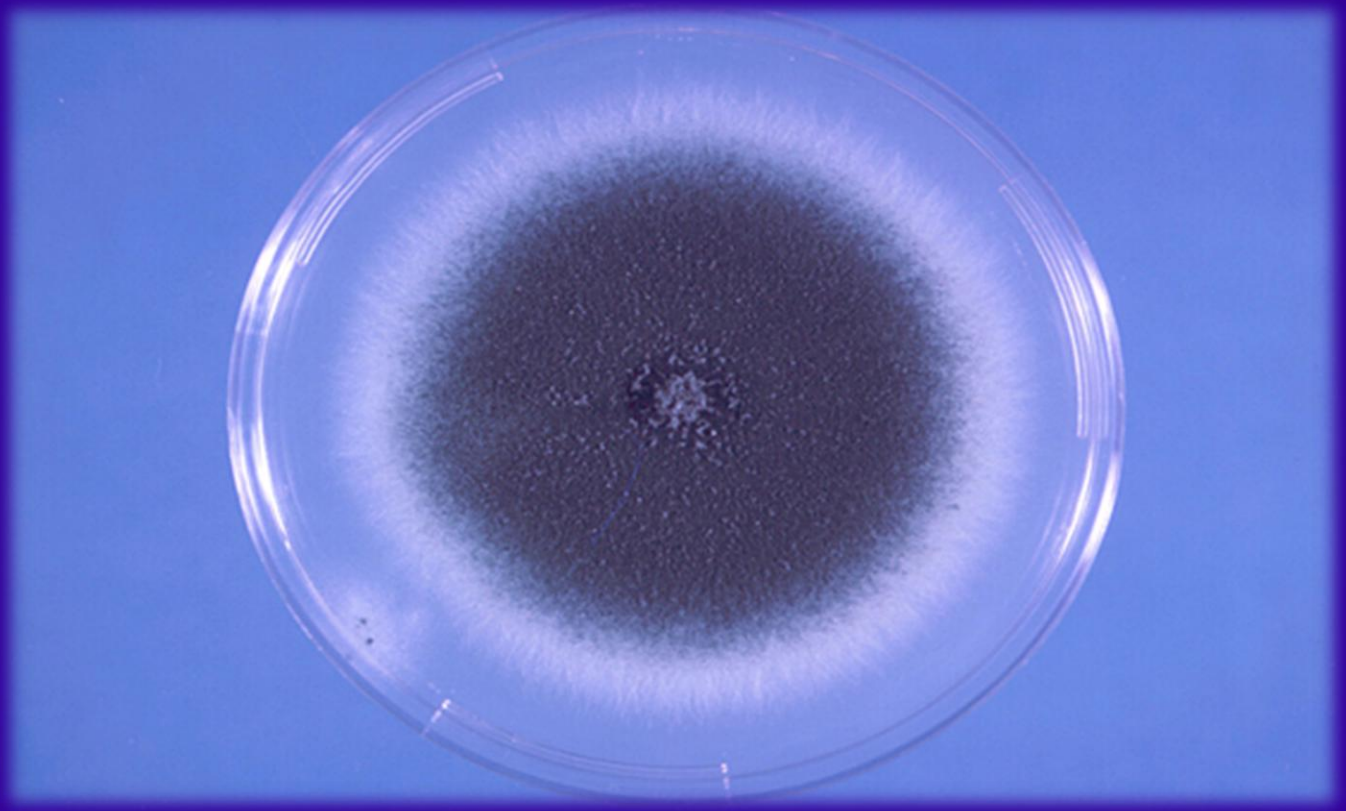

Réaction allergique

- **Les aspergilloses immuno-allergiques**
  - ***L'asthme*:**
    - **Présentation classique**
    - **Aspergillus= allergène**
    - **Biologie: hyperéosinophilie, IgE spécifique anti-aspergillaires**
    - **Prise en charge classique**

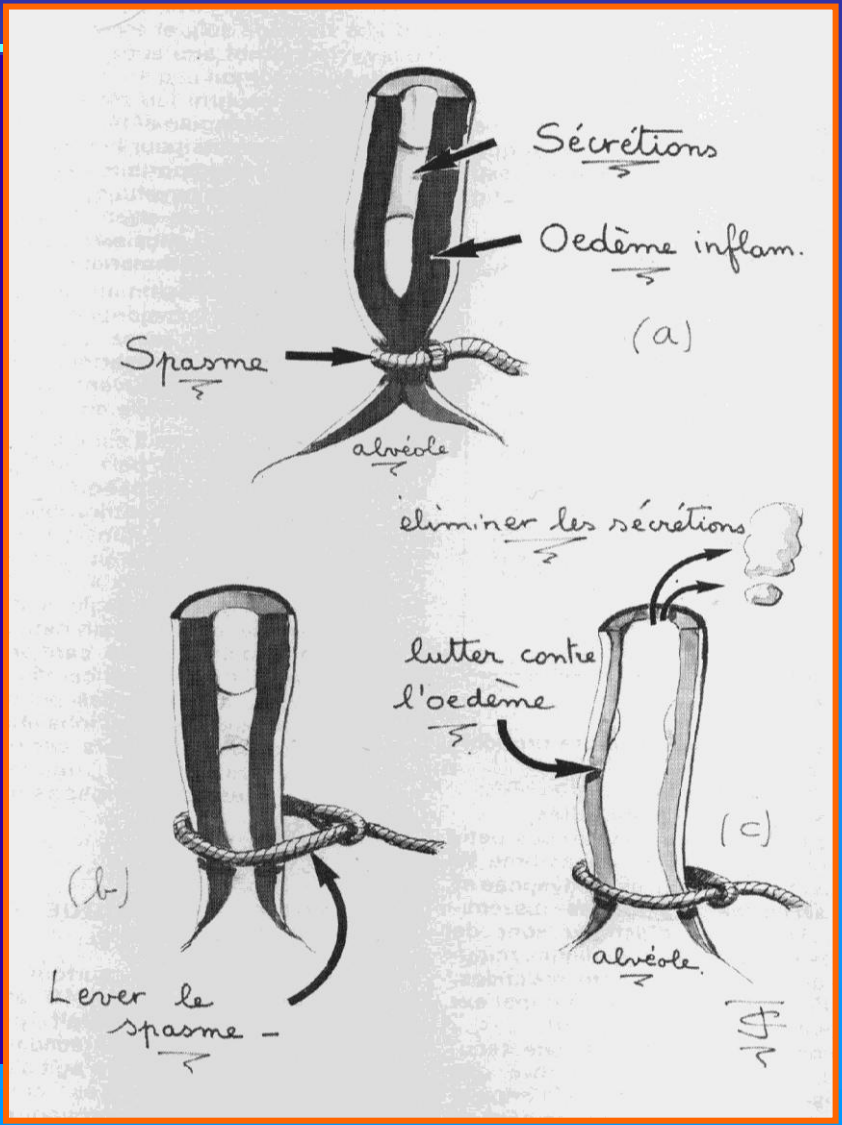

Réaction allergique

- **Les aspergilloses immuno-allergiques**

  – ***L'aspergillose bronchopulmonaire allergique (ABPA):***

    - **Terrain propice: asthme, atopie, mucoviscidose…**
    - **Réponse immunitaire locale à une colonisation trachéo-bronchique aspergillaire chronique**

    - **Symptômes: dyspnée fébrile**
      toux
      expectoration plugs brunâtres

Réaction allergique

- **Les aspergilloses immuno-allergiques**

  - ***L'aspergillose bronchopulmonaire allergique (ABPA):***

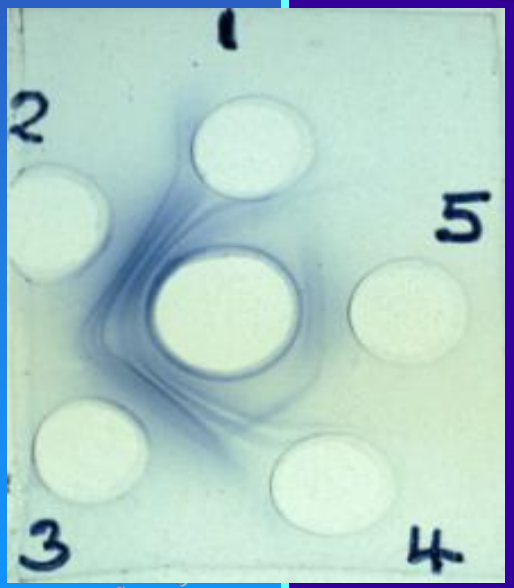

    - **Diagnostic:**
      - **Biologique: hyperéosinophilie sanguine (>500/mm³)**
        IgE totale augmentée (>1000 ng/ml)
        précipitines aspergillaires
        IgA, IgG: augmenté
        IgE et IgG spécifiques augmentés (x2)
      - **Test cutané pour aspergillus positif**
      - **Radiologique: infiltrats migrants voire atélectasies**
        Bronchiectasies centrales
        Fibrose au stade terminal

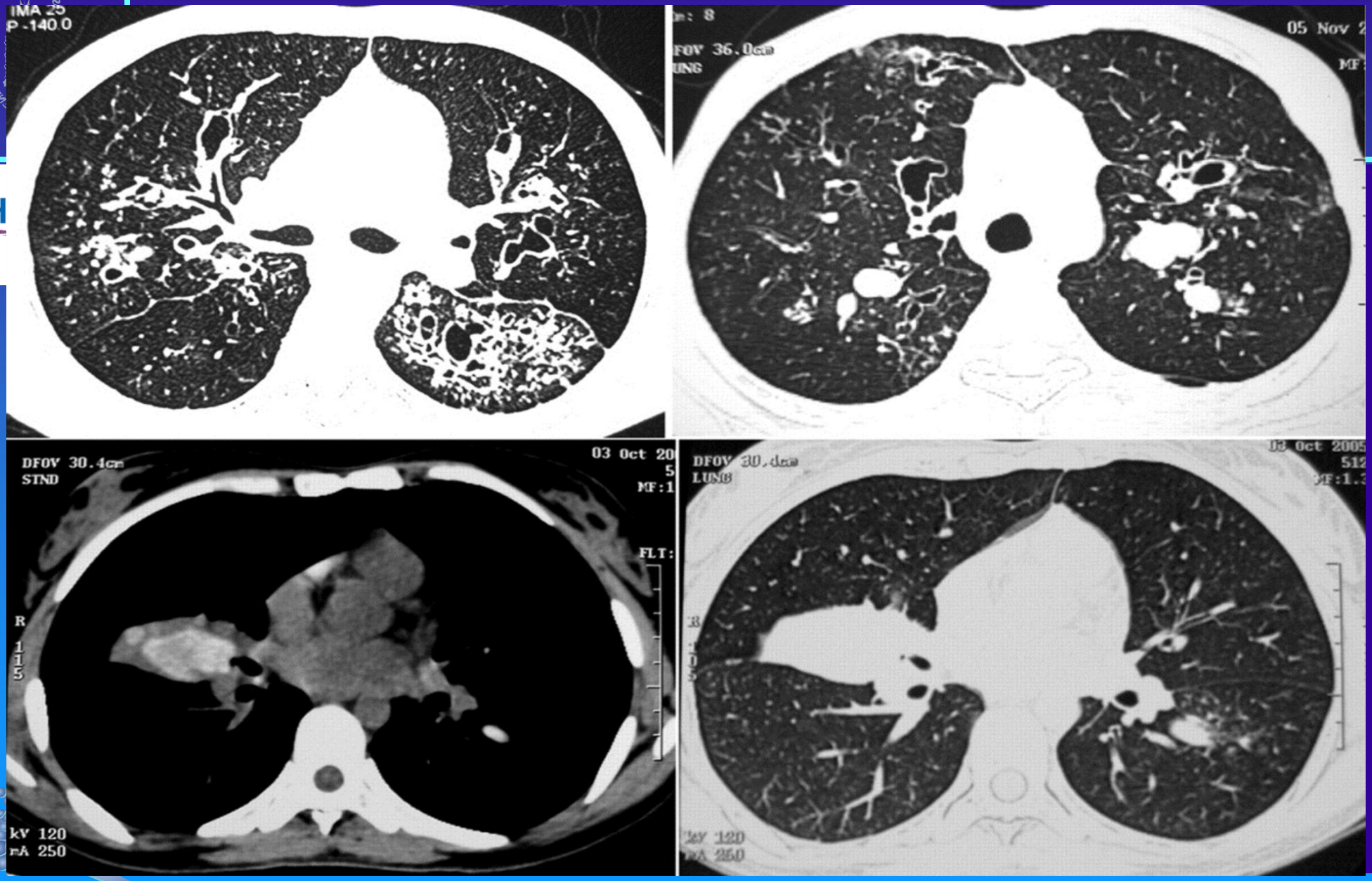

Chest. 2009;135(3):805-826

Réaction allergique

- **Les aspergilloses immuno-allergiques**
  - ***L'aspergillose bronchopulmonaire allergique (ABPA):***
    - **Traitement:**
      - **Antifungique (16 sem): itraconazole**
        Voriconazole?
      - **Corticothérapie: corticorésistance fréquente**
      - **Autres: omalizumab (Xolair®): possible efficacité**

Réaction allergique

- **Pneumonie d'hypersensibilité (=alvéolite allergique extrinsèque)**
  - **Physiopathologie:**
    - **Inhalation importante de spores aspergillaires**
    - **Foin ou grain moisi**
    - **Poumon de fermier**

Réaction allergique

- **Pneumonie d'hypersensibilité (=alvéolite allergique extrinsèque)**
  - **Symptômes:**
    - **Fièvre, parfois élevée**
    - **Dyspnée**
    - **Toux**
    - **Crépitants à l'auscultation**
    - **Comme une pneumonie aiguë = y penser si exposition**
    - **Si exposition répétée risque de fibrose pulmonaire**

Réaction allergique

- **Pneumonie d'hypersensibilité (=alvéolite allergique extrinsèque)**
  - **Diagnostique:**
    - **Radiologie**

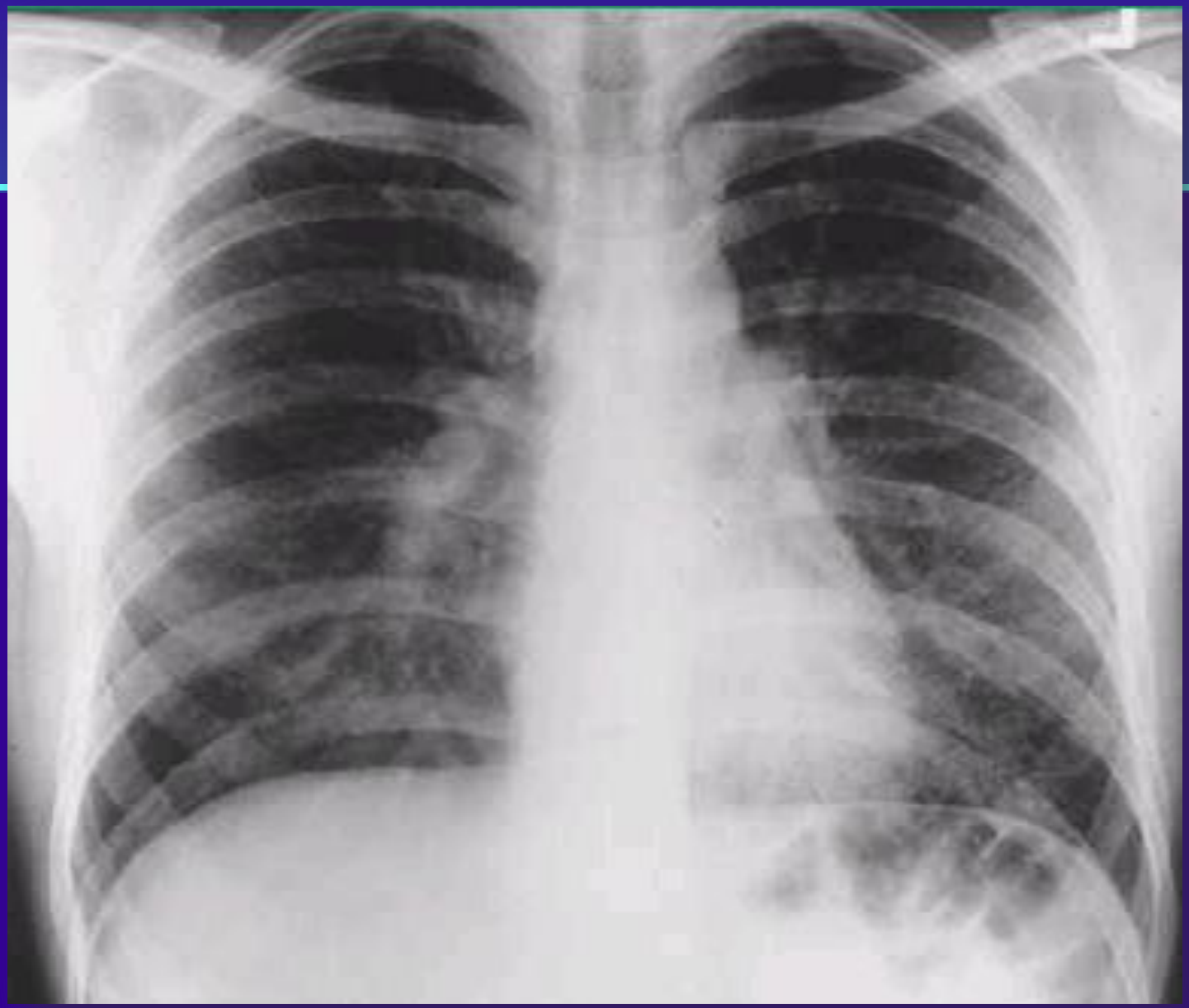

UpToDate®

UpToDate®

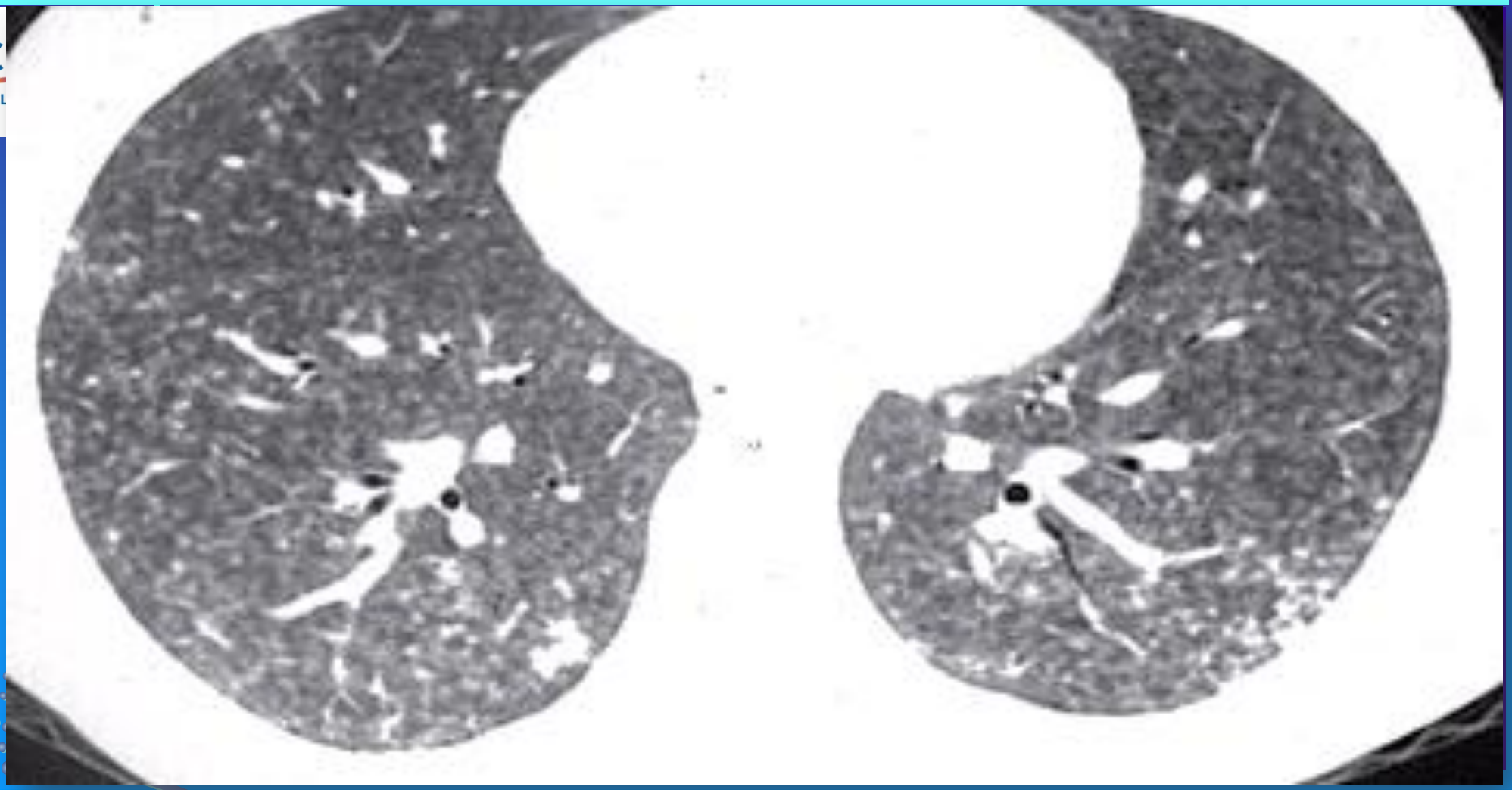

UpToDate®

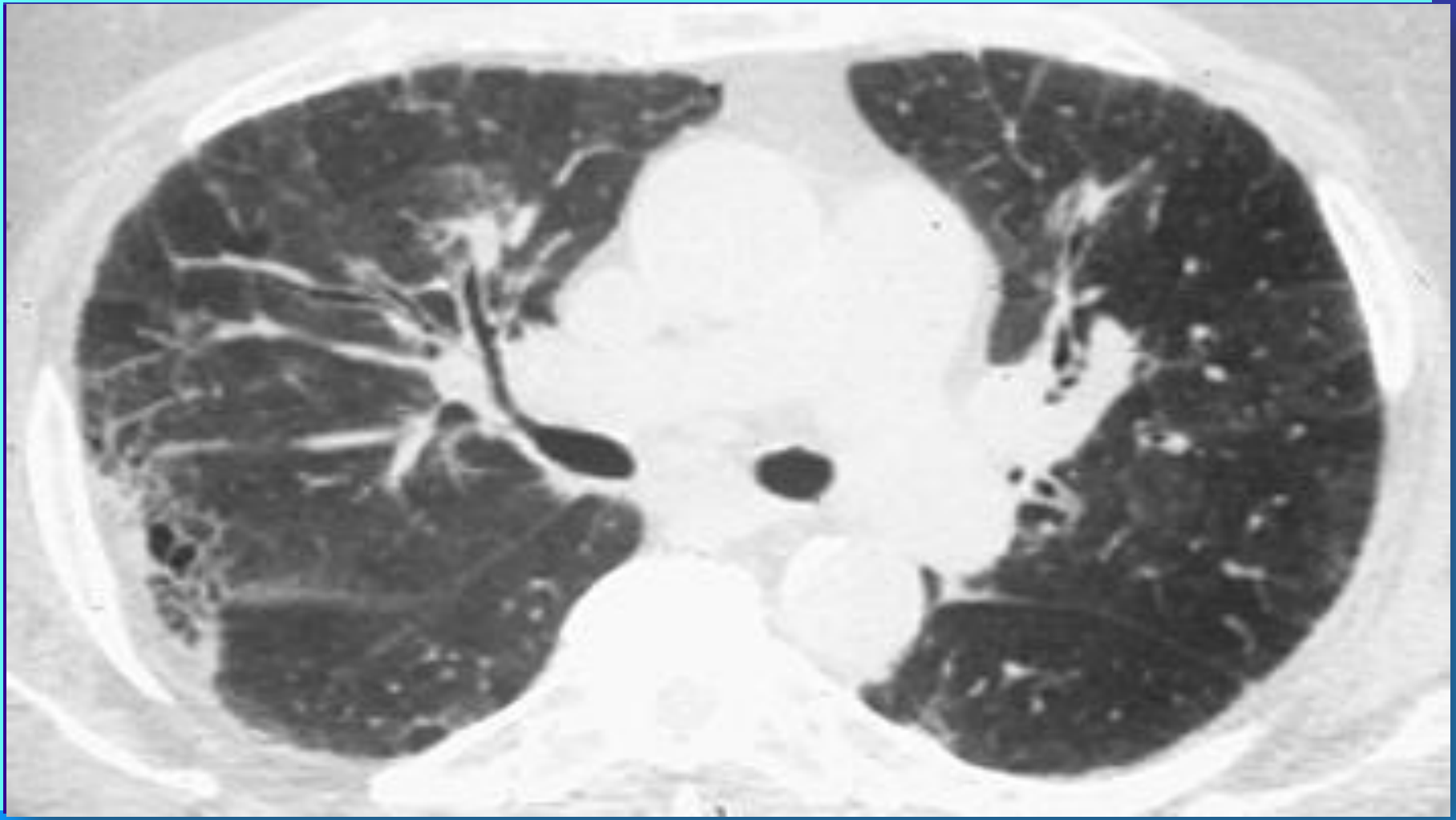

UpToDate®

Réaction allergique

- **Pneumonie d'hypersensibilité (=alvéolite allergique extrinsèque)**
  - **Diagnostique:**
    - **Radiologie**
    - **Sérologie: précipitines peuvent être présentes**
    - **LBA: majoritairement des lymphocytes (>20%)**
      CD4/CD8 <1
      [CD3+/CD8+/CD56+/CD57+/CD10-]
      hyaluronic acid and procollagen 3 N-terminal peptide
    - **BTB**
    - **EFR: restrictive, obstructif, mixte**
      Diminution DLCO
    - **Test de provocation/exposition**

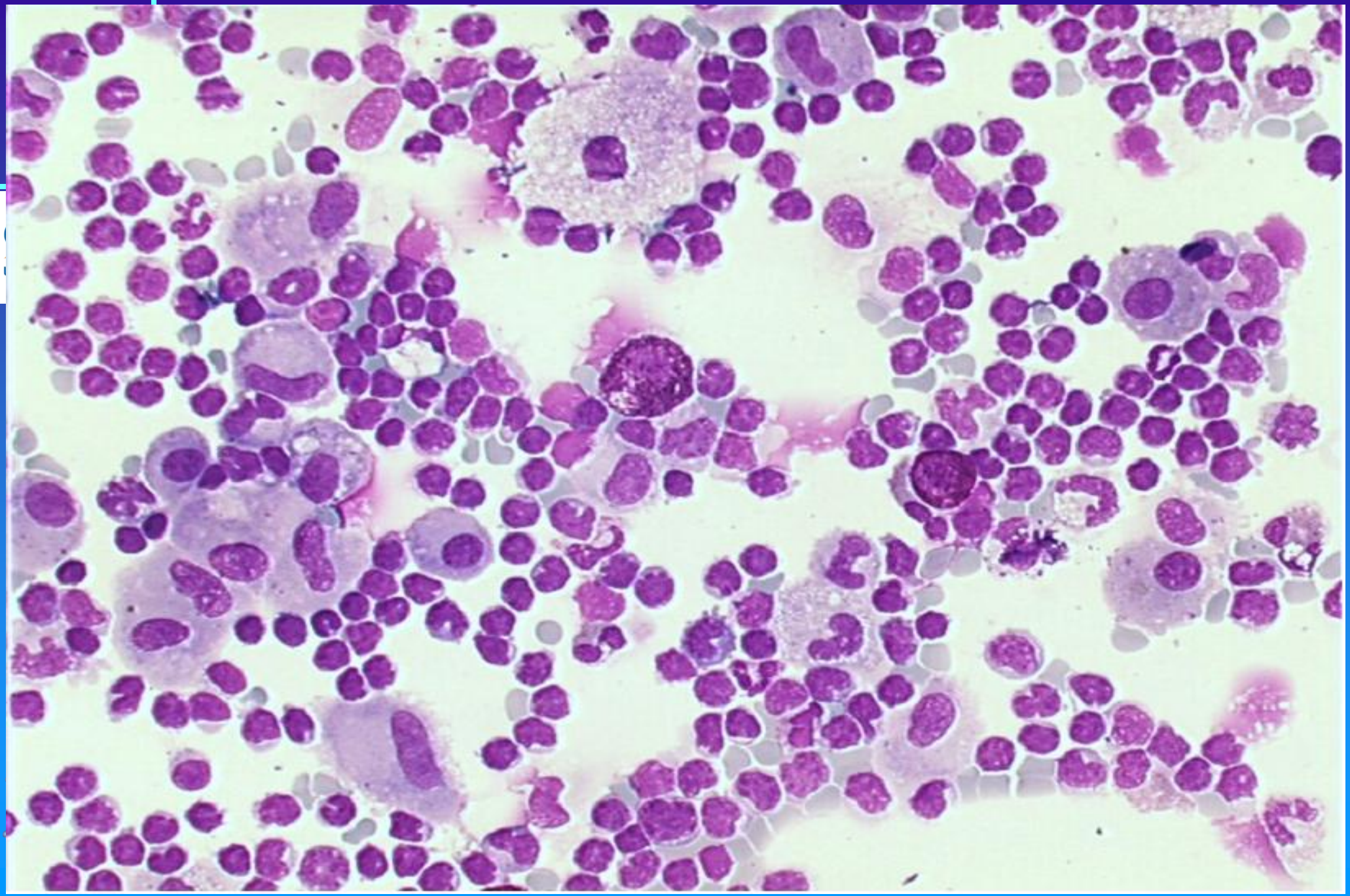

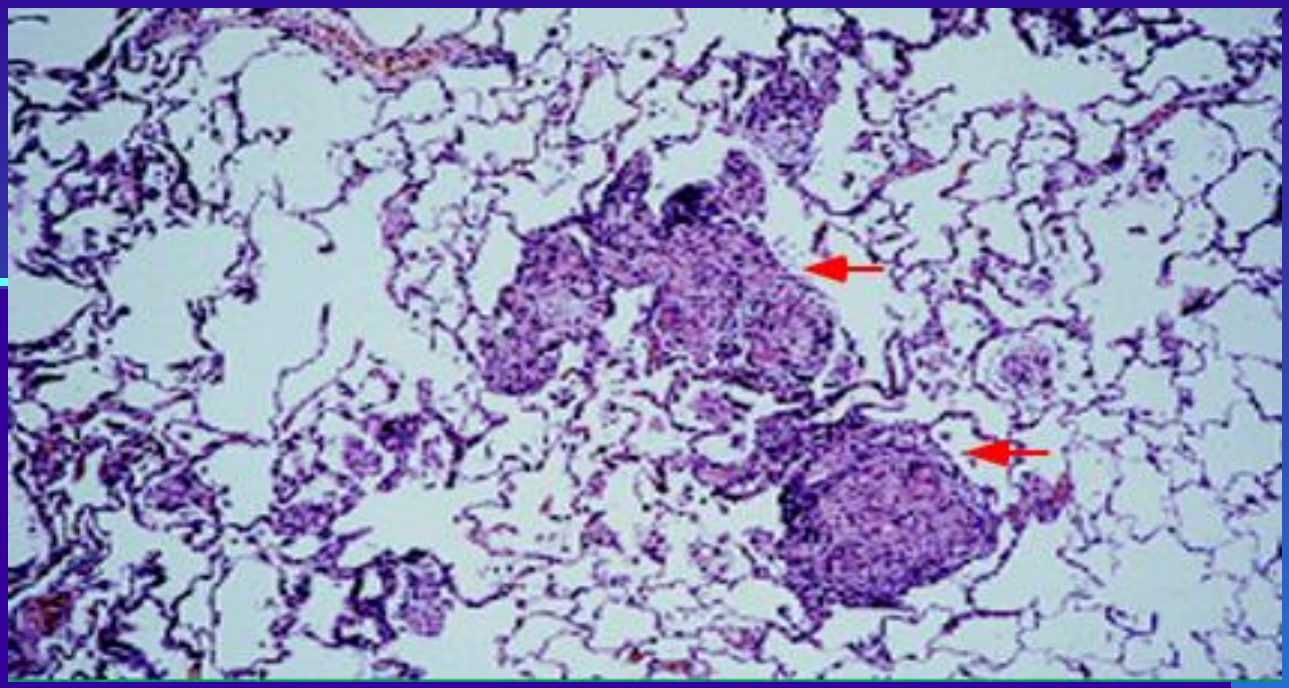

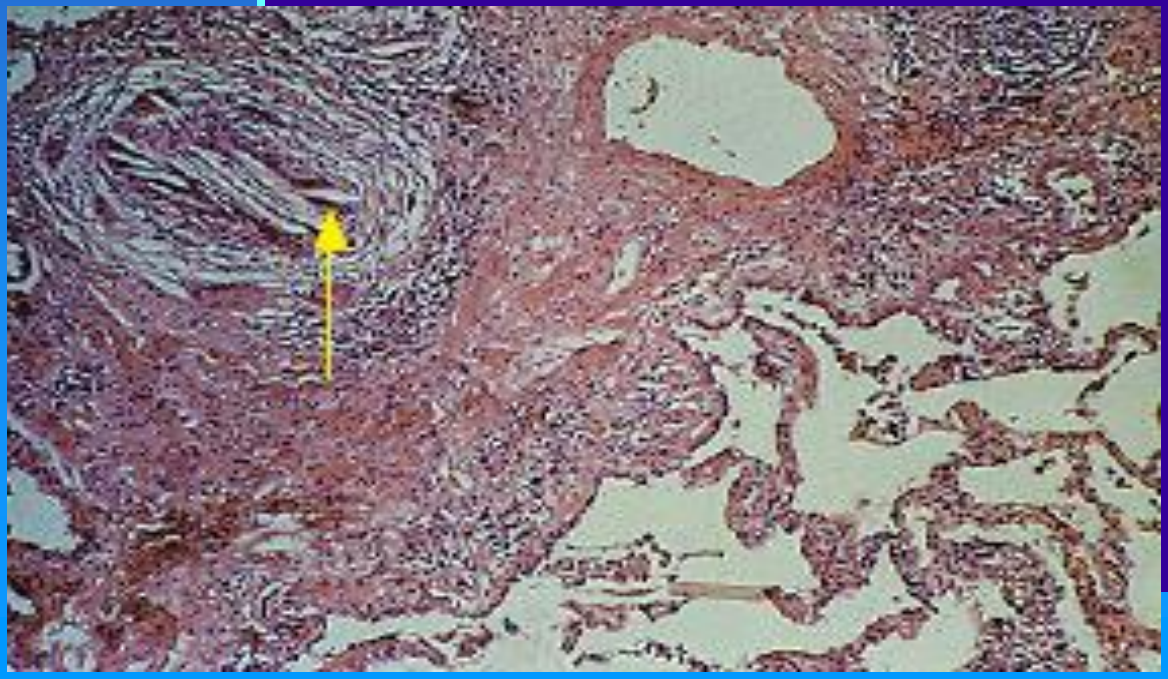

UpToDate®

Hypersensitivity pneumonitides associated with farming

Environmental source	Major causative antigen
Moldy hay, grain, silage	Thermophilic actinomycetes, such as Faenirecti virgula (also known as Micropolyspora faeni or Saccharopolyspora rectivirgula)
	Fungus, such as Aspergillus umbrosus
Mold on pressed sugar cane (bagassosis, very rare cases)	Thermoactinomyces sacchari, T. vulgaris
Tobacco plants (tobacco grower's lung; "Blackfat" tobacco)	Aspergillus sp
	Scopulariopsis brevicaulis
Mushroom worker's lung	Mushroom spores
	Thermophilic actinomycetes
Potato riddler's lung (moldy hay around potatoes)	Thermophilic actinomycetes
	T. vulgaris
	F. rectivirgula
	Aspergillus sp
Paprika slicer's lung (moldy paprika pods)	Mucor stolonifer
Wine maker's lung (mold on grapes)	Botrytis cincrea
Cheese washer's lung (moldy cheese)	Penicillium casei
	Aspergillus clavatus
Coffee worker's lung	Coffee-bean dust
Tea grower's lung	Tea plants

UpToDate®

Réaction allergique

- **Pneumonie d'hypersensibilité (=alvéolite allergique extrinsèque)**
  - **Traitement:**
    - **EVICTION**
    - **Corticoïdes: surtout efficace en aigu**
  - **Pronostic: souvent persistance de déficit ventilatoire obstructif modéré mais évolution vers fibrose possible**

Lésion «anatomique» préexistante

- **L'aspergillome**
  - Colonisation d'une cavité préformée:
    - Séquelle tuberculose
    - Bulle emphysème
    - Bronchiectasie,…
  - Symptômes:
    - Variable en fonction de la taille et localisation
    - D'asymptomatique à hémoptysie massive
    - Fièvre résistante aux antibiotiques
    - Toux ± expectorations
    - AEG

Lésion «anatomique» préexistante

- **<u>L'aspergillome:</u>**
  - **Diagnostique:**
    - **Radiologique**
    - **Sérologique**

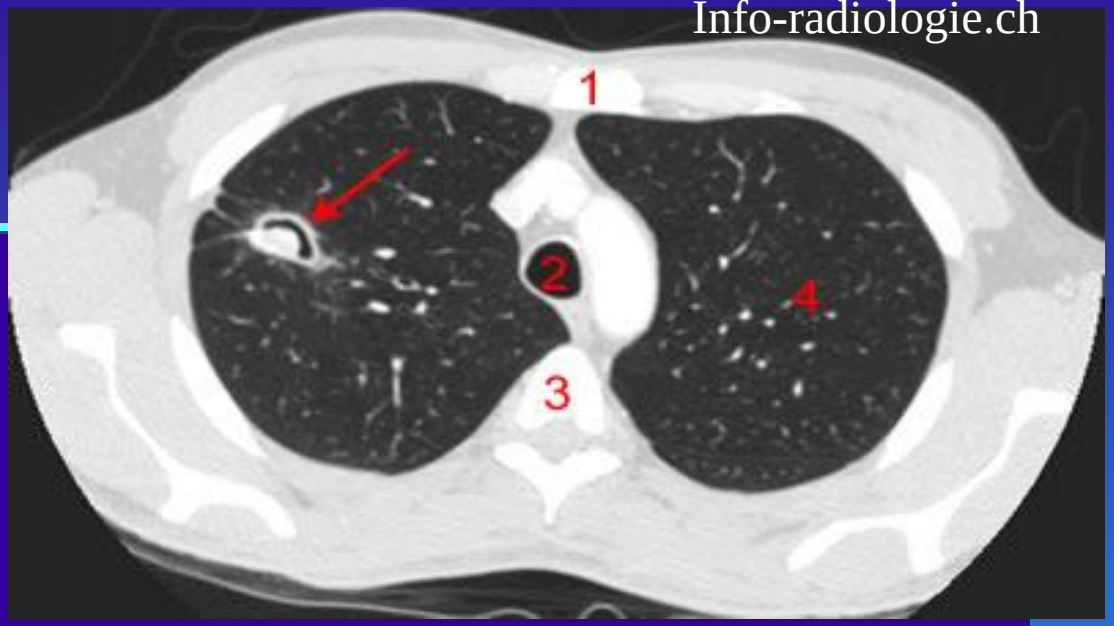
Info-radiologie.ch
1
2
3
4

DFOV 35.0cm
LUNG
Respir.com

Lésion «anatomique» préexistante

- **L'aspergillome:**
  - **Traitement:**
    - **Symptomatique mais surveillance nécessaire**
    - **Antifungique: intérêt limité**
      AmB en instillation?
    - **Si hémoptysies récidivantes:**
      - **Embolisation: souvent pour stabiliser avant chir.**
      - **Chirurgie: wedge, segmentectomie, lobectomie, pneumonectomie**
        prévoir AFθ (svt voriconazole)

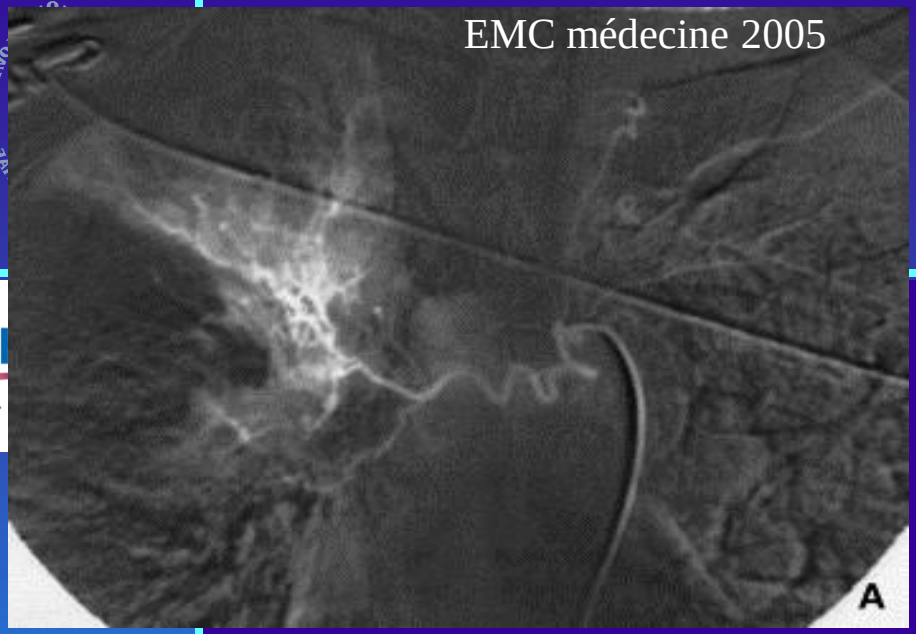
EMC médecine 2005
A

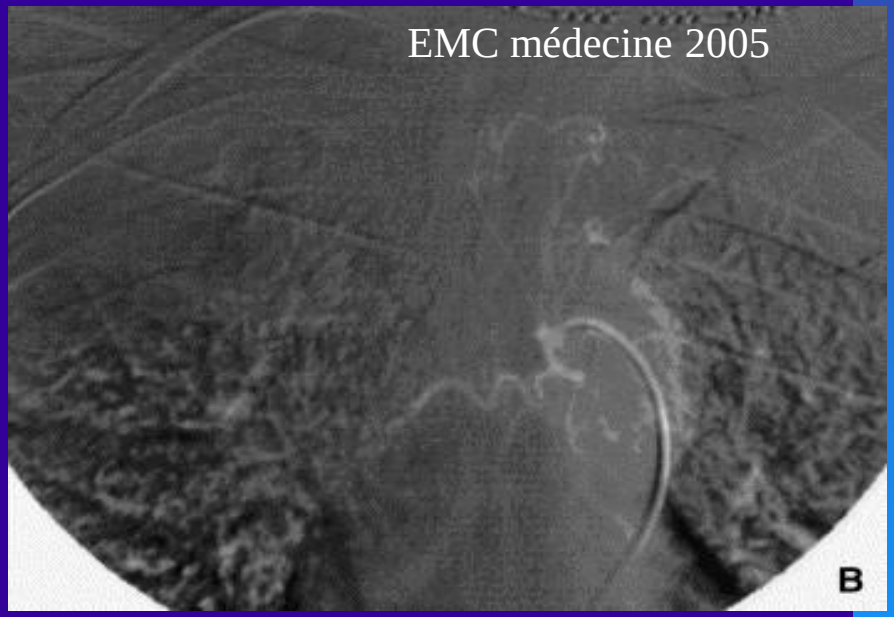
EMC médecine 2005
B

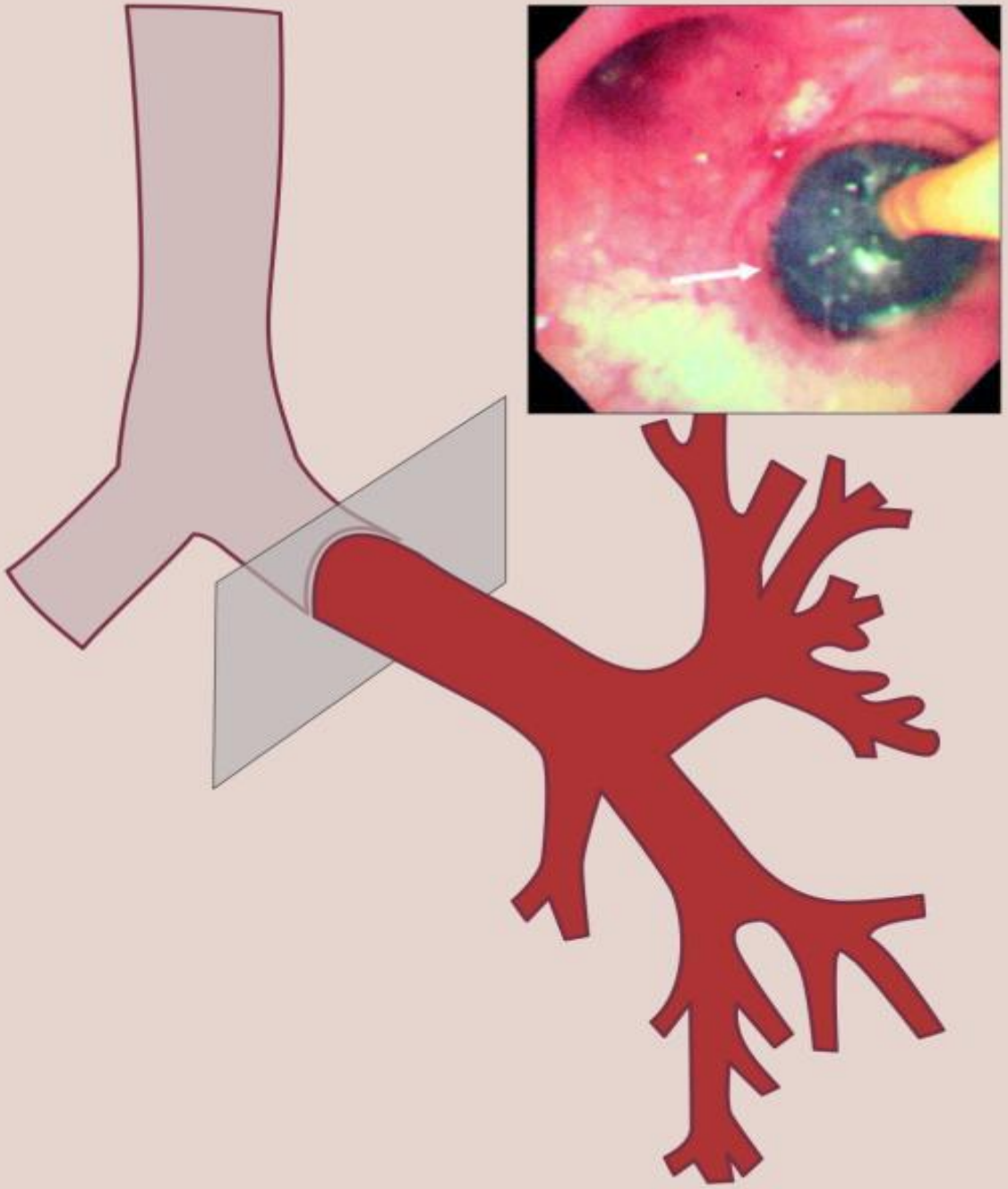

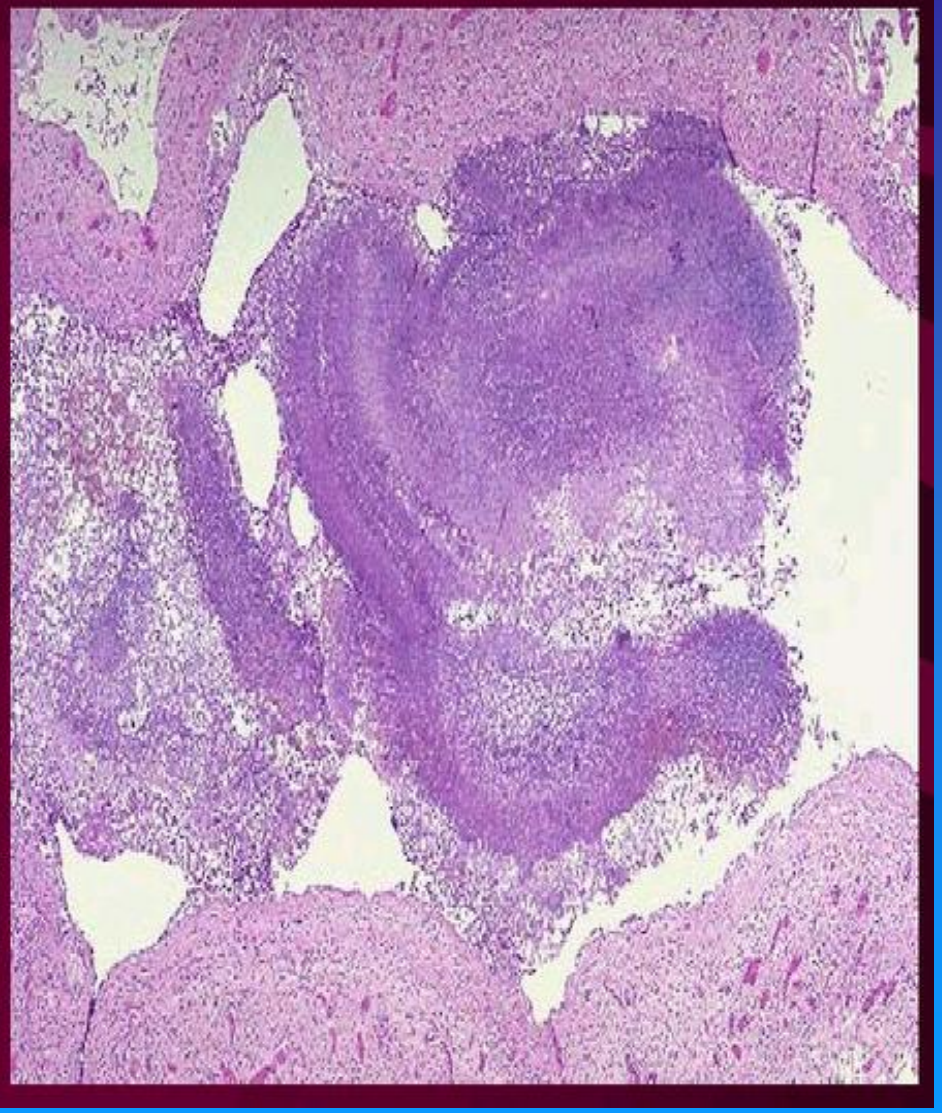

Présentation Dr Tilani, Tunis

Immunité modérément perturbée

- **L'aspergillose pulmonaire chronique**
  - **Définitions:**
    - Aspergillose chronique cavitaire
    - Aspergillose chronique fibrosante
    - Aspergillose chronique nécrosante

Underlying diseases in patients with chronic pulmonary aspergillosis

Common underlying diseases
Pulmonary tuberculosis
Nontuberculous mycobacterial infection
Allergic bronchopulmonary aspergillosis
Treated lung cancer
Pneumothorax (often related to a bulla)
Chronic obstructive pulmonary disease
Sarcoidosis (stage II/III)
Uncommon underlying diseases
Rheumatoid arthritis with pulmonary nodules
Ankylosing spondylitis
Thoracic surgery
Asthma
Radiotherapy to the thorax or chest wall
Community-acquired pneumonia
Invasive pulmonary aspergillosis
Cannabis lung
Pneumoconiosis
Histoplasmosis
Silicosis

UpToDate®

Immunité modérément perturbée

- **L'aspergillose pulmonaire chronique**
  - ***Aspergillose chronique cavitaire*** **(=Aspergillome complexe)**
    - **Terrain: patient «immunocompétent »**
    - **Symptômes: AEG, transpiration nocturne, toux chronique, hémoptysie**
    - **Diagnostique: Radiologique**
      Sérologique: IgG antiaspergillaire
    - **Traitement: - le + souvent: AFθ (itra-, vori-, posa-conazole)**
      - si pas de réponse:
      - embolisation si hémoptysie
      - chirurgie peu indiquée



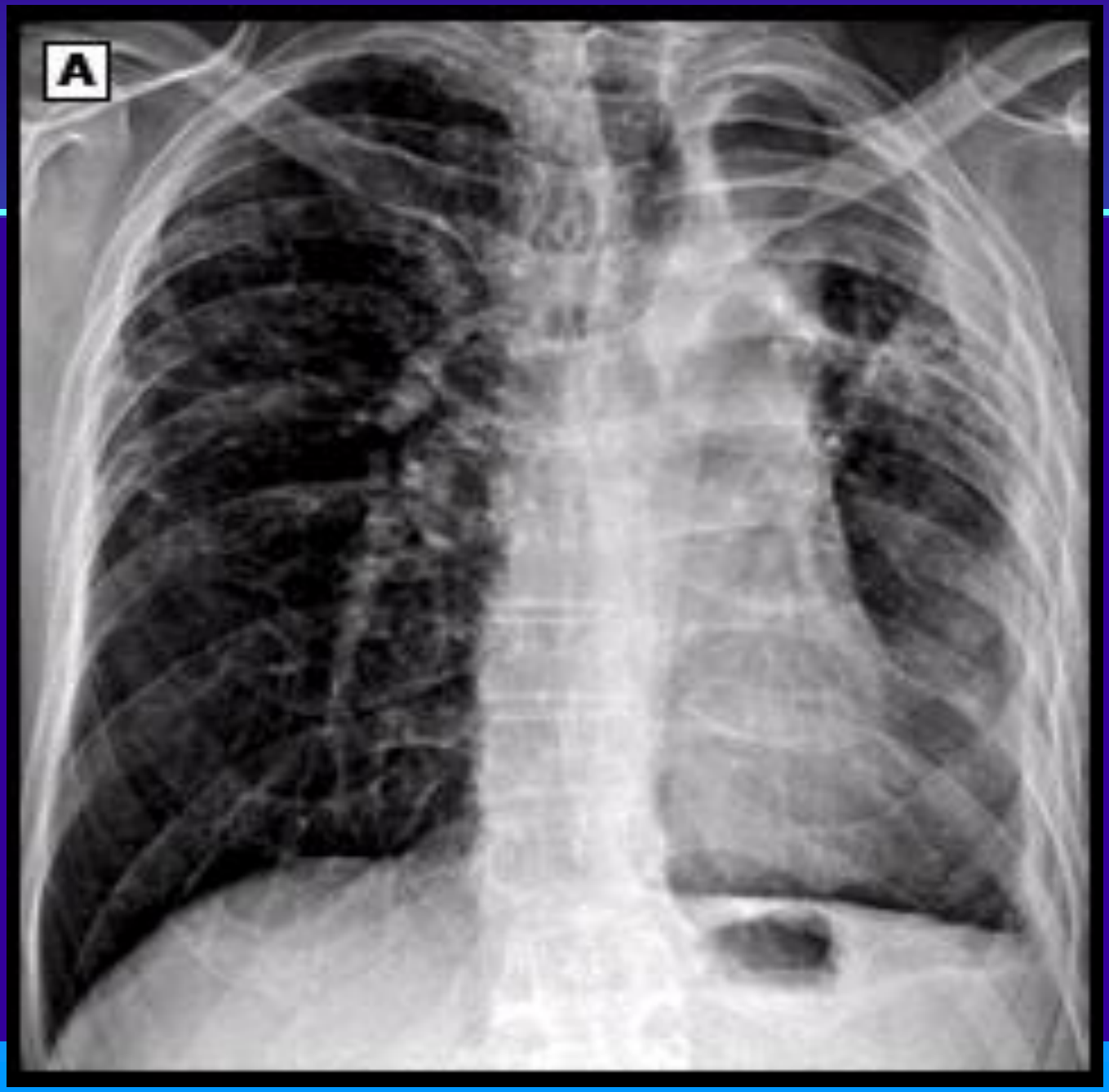

UpToDate®

Immunité modérément perturbée

- **<u>L'aspergillose pulmonaire chronique</u>**
  - ***Aspergillose chronique fibrosante***
    - **= évolution terminale aspergillose chronique cavitaire**
    - **Terrain: patient immunocompétent**
    - **Symptômes: AEG, transpiration nocturne, toux chronique, hémoptysie**
    - **Diagnostique: Radiologique**
      Sérologique: IgG antiaspergillaire
    - **Traitement: cfr Aspergillose chronique cavitaire**



Chronic pulmonary aspergillosis

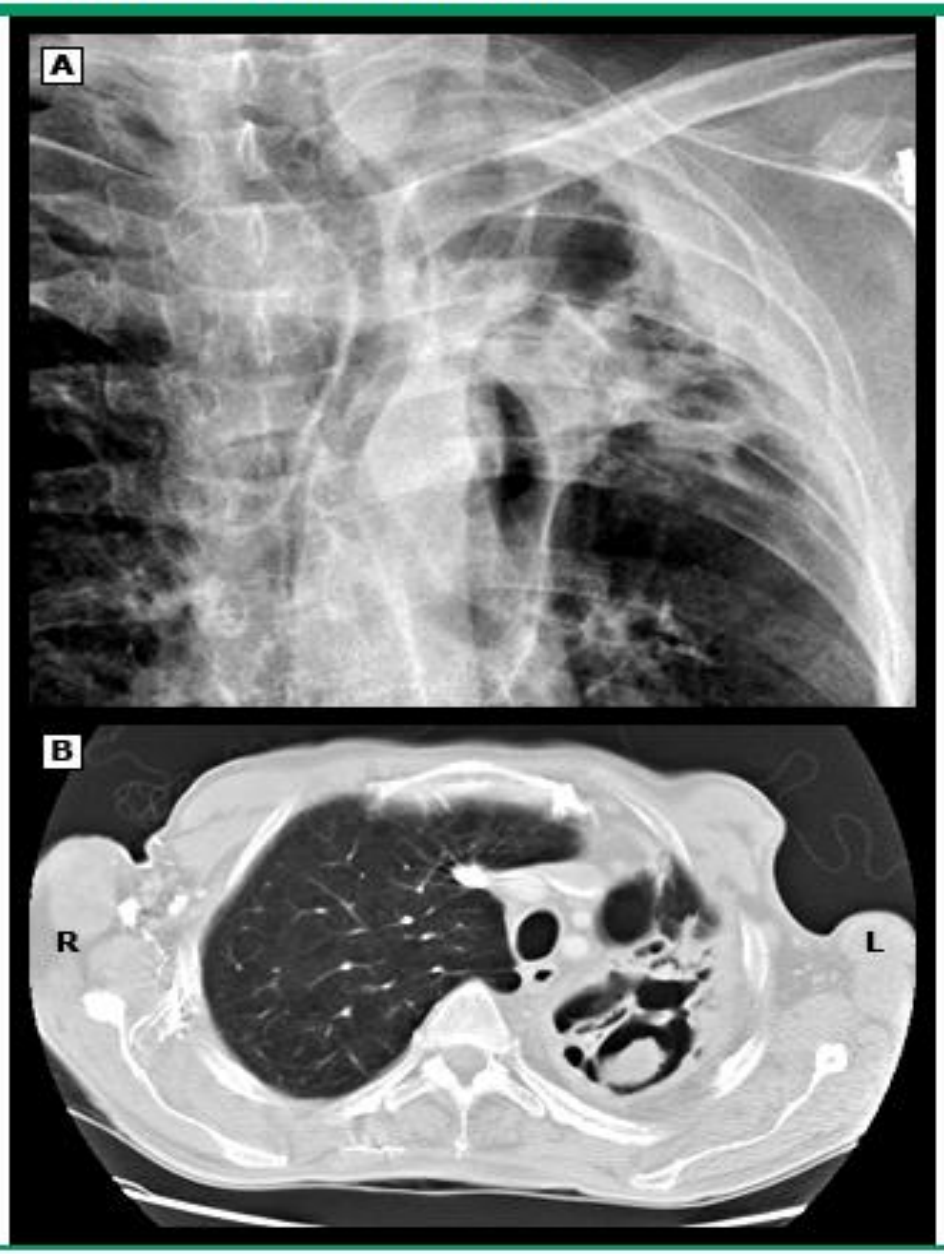

UpToDate®

Chronic pulmonary aspergillosis

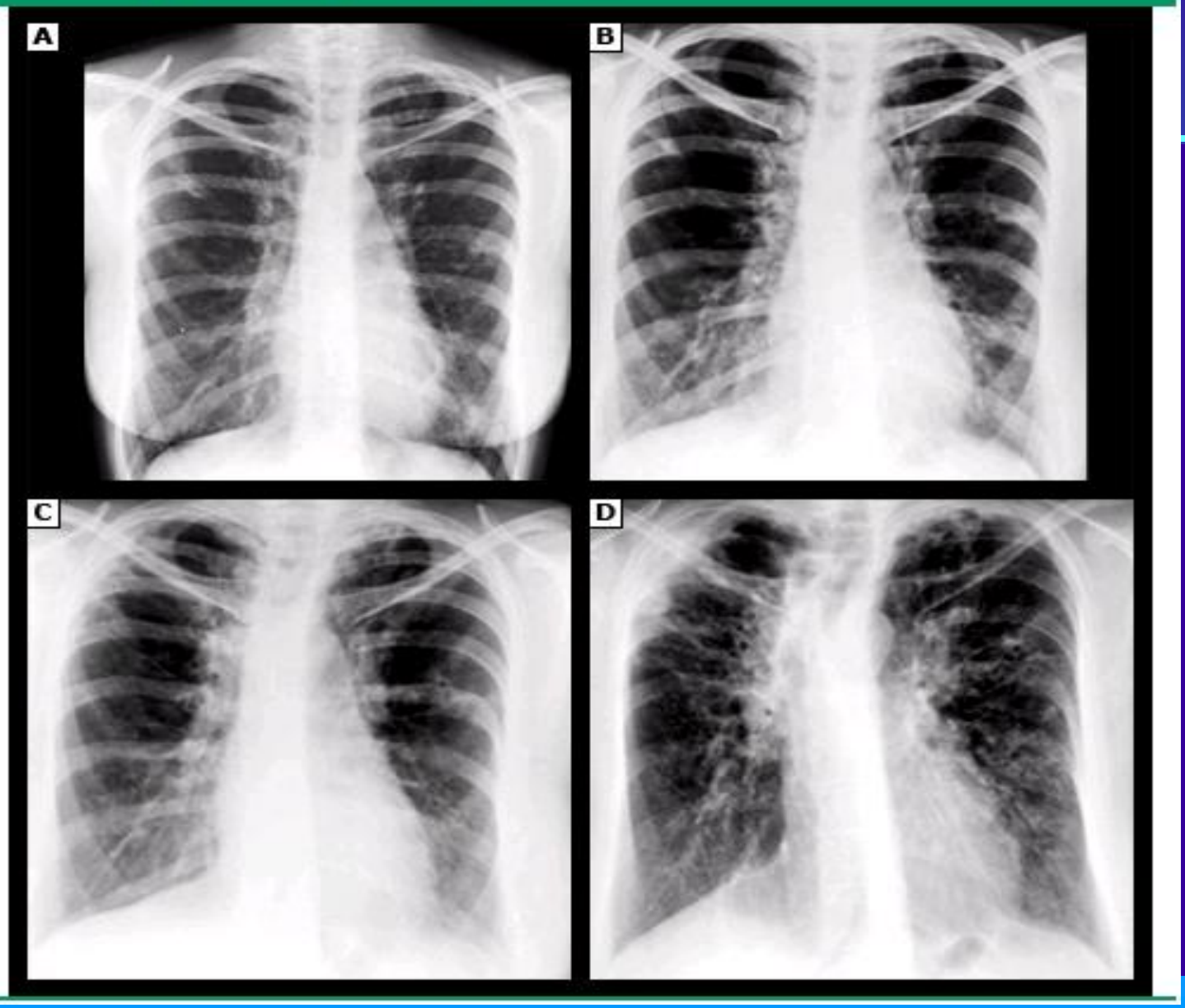

UpToDate®

Immunité modérément perturbée

- **L'aspergillose pulmonaire chronique**
  - ***Aspergillose chronique nécrosante*** **(= aspergillose pulmonaire invasive semi-aiguë, aspergillose semi-invasive)**
    - **Terrain: patient modérément immunodéprimé**
      Diabète, Alcool, corticoïdes
    - **Pathologie: invasion des tissus**
    - **Symptômes: AEG, transpiration nocturne, toux chronique, hémoptysie**
    - **Diagnostique: Radiologique**
      Sérologique: IgG antiaspergillaire
      parfois galactomannan
      Biopsies
    - **Traitement: AFθ: itra- ou vori-conazole**

Immunité modérément perturbée

- **L'aspergillose pulmonaire chronique**
  - ***Traitement:***
    - **Durée: longue, voire très longue**
    - **Réponse: voir sérologie, Rx et symptômes**
    - **Taux de réponse: 60 à 80%**
    - **Biodisponibilité AF**
    - **Résistance aux azolés**
    - **Pensez aux co-infections**
  - ***Pronostique: morbidité et mortalité élevée***

L'aspergillose pulmonaire invasive



CHU Dinant Godinne
UCL NAMUR

INTRODUCTION

Physiopathologie

- Germination des spores
- Prolifération des hyphes (facteurs de virulence?)
- Envahissement local: - parenchyme
  - vaisseaux => infarctus

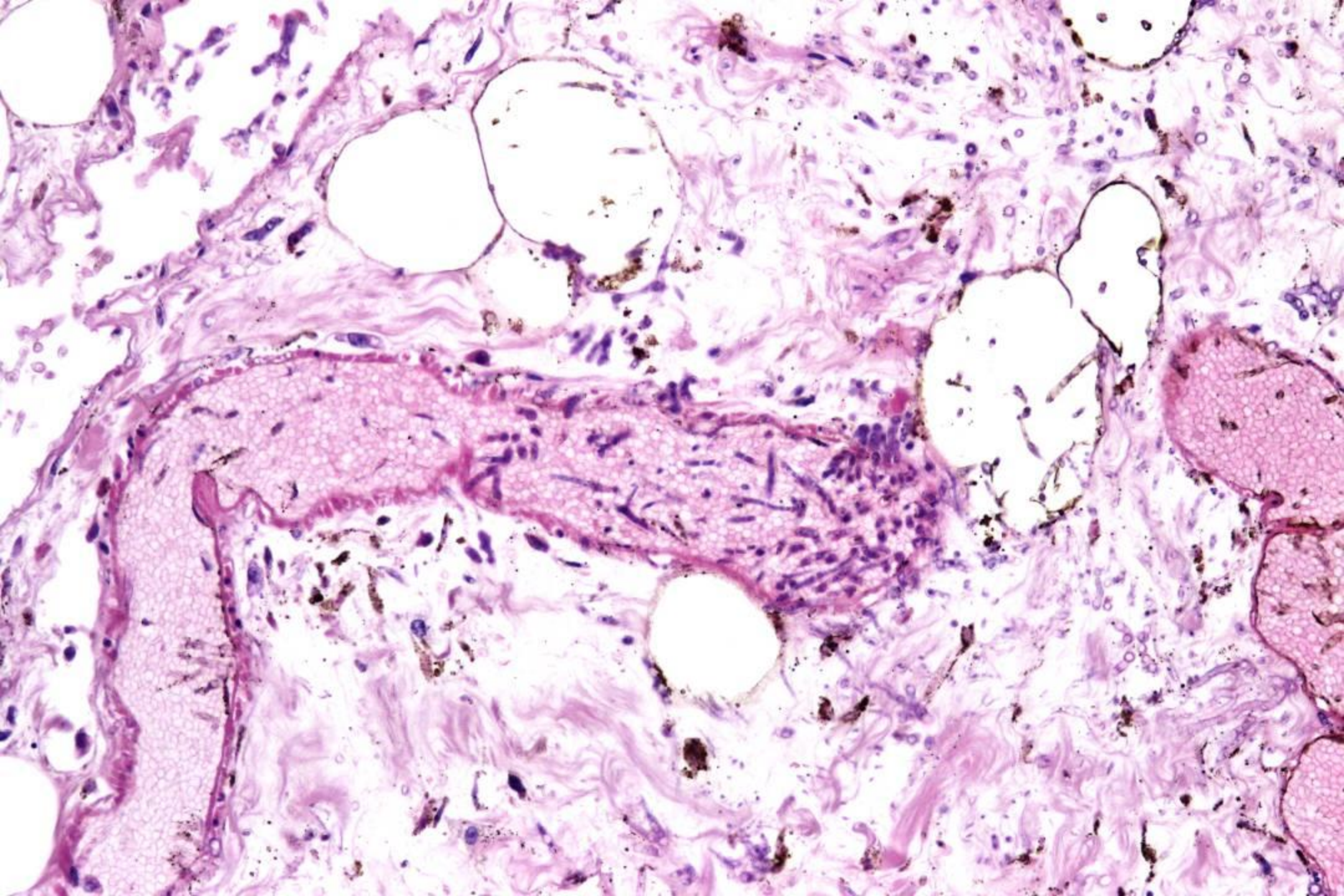

INTRODUCTION

Défenses de l'organisme:

- première ligne: macrophages alvéolaires
  destruction des conidies

- deuxième ligne: neutrophiles
  destruction des hyphes

EPIDEMIOLOGIE

- Incidence inconnue
- Diagnostic infection vs colonisation: difficile

- COPD facteur de risque pour API?
  - 1.3% (26 de 1941)
  - 9% (« atteinte pulmonaire ») sur 595 pts
  - 1% de tous les pts souffrant d'API

- Prednisone: >20mg/j
  700mg cumulatif

- Virus: Influenza; CMV

Clin Infect Dis 2001; 32: 358-366; Medicine 2000; 79: 250-260; Am J Med 1992; 93: 29-34; Rev Infect Dis 1989; 11: 954–963; Rev Pneumol Clin 1995; 51: 300–301; Curr Infect Dis Rep 2001; 3: 507–516

Predisposing Host Factors and Clinical and Histologic Features Associated with Invasive Pulmonary Aspergillosis

CHU Dinant Godinne UCL NAMUR

Segal B.
N Engl J Med 2009;360: 1870-1884

Table 1. Predisposing Host Factors and Clinical and Histologic Features Associated with Invasive Pulmonary Aspergillosis.*

Population of Patients	Predisposing Host Factors	Clinical and Histologic Features
Acute leukemia, myelodysplastic syndrome, aplastic anemia, and other causes of marrow failure	Neutropenia from chemotherapy or underlying hematologic disease	Hyphal angioinvasion with vascular thrombosis and tissue infarction; scant inflammatory response; possible evolution to cavitation
Allogeneic hematopoietic stem-cell transplantation after neutrophil recovery	Immunosuppression for GVHD (e.g., the use of corticosteroids, T-cell depletion, inhibition of tumor necrosis factor α)	Inflammatory fungal pneumonia and angioinvasion with coagulative necrosis, which are classically associated with neutropenia[32-34]
Solid-organ transplantation	Immunosuppression to prevent allograft rejection	Acute inflammatory pneumonia, chronic necrotizing aspergillosis; tracheobronchitis affecting the anastomotic site and causing dehiscence in lung-transplant recipients
Advanced AIDS	CD4+ T-cell count usually <100 per cubic millimeter; other immunocompromising conditions (e.g., neutropenia)	Acute to slowly progressive necrotizing pneumonia; variable histologic findings: neutrophilic infiltrates, vascular invasion, walled-off abscesses, and cavitation[35]
Chronic granulomatous disease	Defective NADPH oxidase	Acute to slowly progressive pneumonia; pyogranulomatous inflammation without hyphal vascular invasion or coagulative necrosis; "mulch pneumonitis," an acute hypersensitivity response to a large, aerosolized exposure[36]
Preexisting structural lung disease (e.g., emphysema, previous cavitary tuberculosis)	Coexisting conditions (e.g., diabetes and malnutrition) and the use of inhaled and systemic corticosteroids	Chronic necrotizing pulmonary aspergillosis; slowly progressive invasive fungal pneumonia with inflammatory necrosis[37]

* AIDS denotes acquired immunodeficiency syndrome, and GVHD graft-versus-host disease.

Table 1

Patient	Sex	Underlying disease	Age (year)	Last (chemo-)therapy	Reason for admission ICU	Apache II score	Neutrophil count on admission to ICU ($\times 10^9$/l)	Antifungal therapy	Duration of antifungal therapy (days)	Length of stay in ICU (days)	Outcome
1	m	NHL	37	CHOP	Acute renal failure	19	5.5	Ampho B, 5-FC, rifamp	9	22	Died
2	m	TT	22	VIP	Circulatory failure	26	< 0.1	Ampho B	24	24	Died
3	m	SLE	17	Cyclosporine, prednisolone	Resp insuff	21	0.8	Ampho B	1	22	Died
4	m	HCL	53	Alfa-IFN	Resp insuff	20	0.5	Ampho B, itra	17	18	Died
5	m	NHL	33	cCHVP	After resuscitation	30	9.3	Ampho B, itra	44	7	Died
6	m	ALL	61	Vincristine, dauno, asparag., prednisone	Resp insuff	18	1.5	Ampho B, itra	19	10	Died
7	f	CML, BC	44	Vincristine, dauno, asparag., prednisone	Resp insuff	25	< 0.1	Ampho B	1	1	Died
8	m	NHL	24	High dose methylprednisolone, CHOP	Resp insuff	18	0.6	Ampho B	5	36	Died
9	m	NHL	56	IMVP	After resuscitation	50	0.1	Ampho B, itra	1	2	Died
10	m	AML	21	Mitoxantrone-VP-16	Resp insuff	20	< 0.1	Ampho B, itra	58	14	Died
11	m	NHL	59	BEAM, AutoBMT	Resp insuff	29	< 0.1	Ampho B	3	4	Died
12	m	MM	40	Cyclophosphamide, HDM	Resp insuff	23	0.1	Itra, ampho B	15	5	Died
13	m	NDR, ARDS	62	None	Resp insuff	33	8.1*	Ampho B, 5-FC	8	15	Died
14	f	NHL	29	CHOP	Resp insuff	29	< 0.1	Ampho B	1	10	Died
15	m	NHL	45	Cyclophosphamide, HDM	Resp insuff	32	0.1	Ampho B, itra	11	8	Died
16	m	AML	51	Dauno-araC	Massive hemoptysis	9	25.2	Ampho B, itra	16	10	Survived
17	f	NHL	53	BEAM, AutoBMT	Resp insuff	41	0.1	Ampho B, itra	11	4	Died
18	m	MM	53	HDM	Resp insuff	38	0.2	Ampho B	11	5	Died
19	f	AML	52	Dauno-araC	Resp insuff	25	1.2	Ampho B, itra	31	13	Died
20	f	NHL	46	BEAM, AutoBMT	Resp insuff	25	0.3	Ampho B	8	8	Died
21	f	NHL	57	BEAM, AutoBMT	Resp insuff	33	< 0.1	Ampho B	9	4	Died
22	m	MM	57	HDM + PBSCT	Resp insuff	41	0.2*	Ampho B	12	2	Died
23	f	PAN	71	High dose methylprednisolone	Resp insuff	25	13.4*	Ampho B	49	51	Died
24	m	NHL	23	Doxorubicin, cyclophosphamide, methylprednisolone	Resp insuff	32	< 0.1	Ampho B, lip-ampho B	21	24	Died
25	m	AML	63	Dauno-araC	Resp insuff	37	0.4	ABLC[R]	43	16	Survived
Mean			45			28			17	13	
Standard deviation			15			9			16	12	

Intensive Care Med (1996) 22:1315-1322

Case reports

Invasive pulmonary aspergillosis after near-drowning

D. F. Vieira[1,*], H. K. F. Van Saene[2] and D. R. Miranda[3]



Intensive Care Med (1984) 10:203- 204

JAMA. 1979 Apr 6;241(14):1493-4.

Invasive pulmonary aspergillosis associated with influenza.

Fischer JJ, Walker DH.

Rev Mal Respir. 1985;2(4):255-7.

[Invasive pulmonary aspergillosis associated with an acute influenza virus infection]

[Article in French]

Urban P, Chevrolet JC, Schifferli J, Sauteur E, Cox J.

Chest. 1985 May;87(5):691-3.

Invasive pulmonary aspergillosis complicating influenza A pneumonia in a previously healthy patient.

Lewis M, Kallenbach J, Ruff P, Zaltzman M, Abramowitz J, Zwi S.

Rev Pneumol Clin. 1995;51(5):300-1.

[Invasive pulmonary aspergillosis and influenza virus infection in patients with chronic bronchitis?]

[Article in French]

Bulpa P, Dive A, Delos M, P

Respirology. 2005 Jan;10(1):116-9.

Invasive pulmonary aspergillosis associated with influenza B.

Hasejima N, Yamato K, Takezawa S, Kobayashi H, Kadoyama C.

Department of Internal Medicine, Saitama Red Cross Hospital, Saitama, Japan. hase753@par.odn.ne.jp

J Rheumatol. 1999 Jan;26(1):146-9.

Invasive Aspergillus spp infections in rheumatology patients.

Garrett DO, Jochimsen E, Jarvis W.

Hospital Infections Program, National Center for Infectious Diseases, Centers for Disease Control and Prevention, Atlanta, GA 30333, USA.

Semin Arthritis Rheum. 1995 Apr;24(5):304-14.

Invasive aspergillosis in systemic lupus erythematosus.

Gonzalez-Crespo MR, Gomez-Reino JJ.

Rheumatology Unit, Hospital Doce de Octubre, Madrid, Spain.

Lupus. 2009 Jun;18(7):661-6.

Invasive fungal infections in patients with systemic lupus erythematosus: experience from affiliated hospitals of Catholic University of Korea.

Kim HJ, Park YJ, Kim WU, Park SH, Cho CS.

Division of Rheumatology, Department of Internal Medicine, St. Mary's Hospital, The Catholic University of Korea, 62 Yeouido-dong, Yeongdeungpo-gu, Seoul 150-713, Korea.

TABLE 2. CLINICAL CHARACTERISTICS OF PATIENTS WITHOUT HEMATOLOGICAL MALIGNANCY WITH PROVEN OR PROBABLE IA

	All (*n* = 67)	COPD (*n* = 33)	Systemic Disease (*n* = 14)	Liver Cirrhosis (*n* = 3)	Solid Organ Transplants (*n* = 9)	Other (*n* = 8)
Age, yr, mean	65	69	60	55	51	73
SAPS II, mean	52	49	50	64	47	66
Predicted mortality, %	48	43	44	71	40	73
Observed mortality, %	91	85	93	100	100	100
Length of stay, d	21	23	18	13	22	14
Culture positive*	56/67	31/33	10/14	1/3	6/9	8/8
Asp Ag** Positive*	27/51	12/25	7/11	0/0	4/9	4/6
Autopsy positive*	27/41	12/19	6/9	3/3	3/6	3/4

*Tested positive/tested.
**Serum aspergillus antigen (galactomannan assay by means of ELISA).

Meersseman Am J Respir Crit Care Med Vol 170. pp 621–625, 2004

CHU Dinant Godinne UCL NAMUR

Vandewoude

Critical Care 2006, 10:R31

Underlying diseases in intensive care unit patients with respiratory tract samples positive for *Aspergillus* spp.

Underlying condition	Associated with invasive aspergillosis[a]	Associated with *Aspergillus* colonisation
Hematological malignancy[b]	28 (2)	3
With neutropenia	6 (1)	1
Post bone marrow/stem cell transplantation	2	0
Myelodysplastic syndrome	4	-
Solid tumor with chemotherapy	3	1
Solid tumor without chemotherapy	5	3
Graves' disease	-	1
Immunosuppressive therapy	14 (4)	8
Solid organ transplant	8 (2)	4
Auto-immune disease	4 (2)	4
Lung fibrosis	2	0
Aplastic anemia	1	1
Chronic obstructive pulmonary disease	29 (4)	25
Requiring chronic systemic corticosteroid use	21 (3)	12
Requiring inhalation corticosteroids	24 (3)	16
Asthma	2	1
Liver cirrhosis	3 (2)	2
Malnutrition	3	-
Diabetes mellitus	8 (1)	9
Alcoholism	5 (2)	3
Chronic heart failure	6	5
Chronic renal failure – dialysis dependent	3 (1)	2
Lung fibrosis	2	1
Active Cytomegalovirus disease	3	1
Active tuberculosis	-	1
Absence of known underlying disease	14 (5)	27

INVASIVE ASPERGILLOSIS

“NEW” risk factors:

- Corticosteroid treatment: prolonged or high doses
- COPD
- Cirrhosis
- Systemic diseases treated by immunosuppressors
- “CARS”



Table 2. Risk of invasive aspergillosis among patients admitted to the intensive care unit (ICU; medical, mixed or surgical).

High-risk category
Neutropenia (neutrophil count, <500 neutrophils/mm^3)
Hematological malignancy
Allogeneic bone marrow transplantation
Intermediate-risk category
Prolonged treatment with corticosteroids before admission to the ICU
Autologous bone marrow transplantation
Chronic obstructive pulmonary disease
Liver cirrhosis with a duration of stay in the ICU >7 days
Solid-organ cancer
HIV infection
Lung transplantation
Systemic diseases requiring immunosuppressive therapy
Low-risk category
Severe burns
Other solid-organ transplant recipients (e.g., heart, kidney, or liver transplant recipients)
Steroid treatment with a duration of ≤7 days
Prolonged stay in the ICU (>21 days)
Malnutrition
Post–cardiac surgery status

Meersseman, CID 2007; 45: 205-16

PHYSIOPATHOLOGIE

- Cils vibratiles
- Système immunitaire: Macro; Neutro; Lympho; Inné
- Corticoïdes:
  - Favorise croissance Aspergillus
  - Diminue immunité
  - ! Durée, ! Corticoïdes inhalés
- « Pneumonie neutrophilique »
- « CARS »

DEFINITIONS (EORTC/MSG)

Table 1. Criteria for proven invasive fungal disease except for endemic mycoses.

Analysis and specimen	Molds[a]
Microscopic analysis: sterile material	Histopathologic, cytopathologic, or direct microscopic examination[b] of a specimen obtained by needle aspiration or biopsy in which hyphae or melanized yeast-like forms are seen accompanied by evidence of associated tissue damage
Culture	
Sterile material	Recovery of a mold or "black yeast" by culture of a specimen obtained by a sterile procedure from a normally sterile and clinically or radiologically abnormal site consistent with an infectious disease process, excluding bronchoalveolar lavage fluid, a cranial sinus cavity specimen, and urine
Blood	Blood culture that yields a mold[d] (e.g., *Fusarium* species) in the context of a compatible infectious disease process
Serological analysis: CSF	Not applicable

Clinical Infectious Diseases 2008; 46:1813–21

CHU Dinant Godinne UCL NAMUR

CID 2008; 46: 1813–21

Table 2. Criteria for probable invasive fungal disease except for endemic mycoses.

- Host factors[a]
  - Recent history of neutropenia (<0.5 × 10^9 neutrophils/L [<500 neutrophils/mm^3] for >10 days) temporally related to the onset of fungal disease
  - Receipt of an allogeneic stem cell transplant
  - Prolonged use of corticosteroids (excluding among patients with allergic bronchopulmonary aspergillosis) at a mean minimum dose of 0.3 mg/kg/day of prednisone equivalent for >3 weeks
  - Treatment with other recognized T cell immunosuppressants, such as cyclosporine, TNF-α blockers, specific monoclonal antibodies (such as alemtuzumab), or nucleoside analogues during the past 90 days
  - Inherited severe immunodeficiency (such as chronic granulomatous disease or severe combined immunodeficiency)
- Clinical criteria[b]
  - Lower respiratory tract fungal disease[c]
    - The presence of 1 of the following 3 signs on CT:
      - Dense, well-circumscribed lesions(s) with or without a halo sign
      - Air-crescent sign
      - Cavity
  - Tracheobronchitis
    - Tracheobronchial ulceration, nodule, pseudomembrane, plaque, or eschar seen on bronchoscopic analysis
  - Sinonasal infection
    - Imaging showing sinusitis plus at least 1 of the following 3 signs:
      - Acute localized pain (including pain radiating to the eye)
      - Nasal ulcer with black eschar
      - Extension from the paranasal sinus across bony barriers, including into the orbit
  - CNS infection
    - 1 of the following 2 signs:
      - Focal lesions on imaging
      - Meningeal enhancement on MRI or CT
  - Disseminated candidiasis[d]
    - At least 1 of the following 2 entities after an episode of candidemia within the previous 2 weeks:
      - Small, target-like abscesses (bull's-eye lesions) in liver or spleen
      - Progressive retinal exudates on ophthalmologic examination
- Mycological criteria
  - Direct test (cytology, direct microscopy, or culture)
    - Mold in sputum, bronchoalveolar lavage fluid, bronchial brush, or sinus aspirate samples, indicated by 1 of the following:
      - Presence of fungal elements indicating a mold
      - Recovery by culture of a mold (e.g., *Aspergillus*, *Fusarium*, Zygomycetes, or *Scedosporium* species)
  - Indirect tests (detection of antigen or cell-wall constituents)[e]
    - Aspergillosis
      - Galactomannan antigen detected in plasma, serum, bronchoalveolar lavage fluid, or CSF
    - Invasive fungal disease other than cryptococcosis and zygomycoses
      - β-D-glucan detected in serum



DEFINITIONS (EORTC/MSG)

Limitations of the revised definitions. The revised definitions apply to immunocompromised patients but not necessarily to critically ill patients in the intensive care unit who, nonetheless, may develop possible or probable IFD [29]. The

Clinical Infectious Diseases 2008; 46:1813–21

DEFINITIONS (USI)

Criteria for defining cases of invasive pulmonary aspergillosis

Definite invasive pulmonary aspergillosis

A. Positive result of histological testing and positive result of culture from lung tissue obtained by biopsy or autopsy

B. Positive result of culture of a specimen obtained from a normally sterile site by use of aseptic invasive technique

Probable invasive pulmonary aspergillosis

1. *Aspergillus*-positive lower respiratory tract specimen culture
2. Compatible signs and symptoms

Fever refractory to at least three days of appropriate antibiotic therapy

Recrudescent fever after a period of defervescence of at least 48 hours while still on antibiotics and without other apparent cause

Pleuritic chest pai

Pleuritic rub

Dyspnoea

Hemoptysis

Worsening respira

Sensibilité 92%	PPV 61%
Spécificité 61%	NPV 92%

3. Abnormal medical imaging by portable chest X-ray or computerised tomography of the lungs
4. Either

a. Host risk factors: one of the following conditions

Neutropenia (absolute neutrophil count less then 500/mm^3) preceding or at the time of ICU admission

Underlying haematological or oncological malignancy treated with cytotoxic agents

Glucocorticoid treatment (prednisone or equivalent, >20 mg/day)

Congenital or acquired immunodeficiency

Or

b. Semiquantitative *Aspergillus*-positive culture of BAL (+ or ++), without bacterial growth together with a positive cytological smear showing branching hyphae

Aspergillus colonisation

Not fullfilling the criteria for proven or probable invasive pulmonary aspergillosis

Crit Care. 2006; 10(1): R31.

AJRCCM 2012; 186:56-64



DEFINITIONS (COPD)

TABLE 1 Definitions of invasive pulmonary aspergillosis (IPA) in chronic obstructive pulmonary disease (COPD) patients

Proven IPA	Histopathological or cytopathological examination, from needle aspiration or biopsy specimen obtained from any pulmonary lesion present for <3 months, showing hyphae consistent with Aspergillus and evidence of associated tissue damage, if accompanied by any one of the following: 1) Positive culture of Aspergillus spp. from any LRT sample. 2) Positive serum antibody/antigen test for *A. fumigatus* (including precipitins). 3) Confirmation that the hyphae observed are those of Aspergillus by a direct molecular, immunological method and/or culture.
Probable IPA	As for proven IPA but without confirmation that Aspergillus is responsible (points 1, 2 and 3 are not present or tested). OR COPD patient, usually treated with steroids and severe according to GOLD (stage III or IV), with recent exacerbation of dyspnoea[#], suggestive chest imaging[¶] (radiograph or CT scan; <3 months[+]) and one of the following: 1) Positive culture[§] and/or microscopy for Aspergillus from LRT. 2) Positive serum antibody test for *A. fumigatus* (including precipitins). 3) Two consecutive positive serum galactomannan tests.
Possible IPA	COPD patient, usually treated by steroids and severe according to GOLD (stage III or IV), with recent exacerbation of dyspnoea[#], suggestive chest imaging[¶] (radiograph or CT scan; <3 months[+]), but without positive Aspergillus culture or microscopy from LRT or serology.
Colonisation	COPD patient with positive Aspergillus culture from LRT *without* exacerbation of dyspnoea, bronchospasm or new pulmonary infiltrate.

Data from references [23] and [38]. LRT: lower respiratory tract; *A. fumigatus*: *Aspergillus fumigatus*; GOLD: Global Initiative for Chronic Obstructive Lung Disease; CT: computed tomography. [#]: Exacerbation of dyspnoea and/or bronchospasm resistant to appropriate treatment including antibiotics; [¶]: pulmonary lesion(s) unresponsive to appropriate antibiotics (refers to dose, route, spectrum and activity against cultured bacteria); [+]: pulmonary lesions, especially cavitary, present for >3 months are better classified as chronic pulmonary aspergillosis (see text), unless direct tissue invasion is demonstrated; [§]: standard or sabouraud culture, or molecular detection test when licensed.

Bulpa ERJ 2007; 30: 782–800

CLINIQUE

Symptômes:

- aspécifique dans 30% des cas (stade précoce)
- toux non productive (hémoptysie)
- fièvre, sauf si corticothérapie
- douleur pleurale
- dyspnée
- auscultation pulmonaire pauvre, aspécifique
- fièvre d'origine inexpliquée

PRONOSTIC

Expérience hollandaise: **(Janssen, Intensive Care Med, 1996)**

- 25 patients admis aux USI, API diagnostiquée avant ou pendant séjour USI, 24/25 pts intubés,
  MORTALITE: 92%

Expérience belge:

- 35 patients admis aux USI, diagnostic API avant ou pendant séjour USI, tous intubés,
  MORTALITE: 100%

PRONOSTIC

Patient characteristics for intensive care unit patients with invasive pulmonary aspergillosis and *Aspergillus* colonisation

Characteristic	Definite invasive aspergillosis ($n = 17$)	Probable invasive aspergillosis ($n = 66$)	Invasive aspergillosis ($n = 83$)	*Aspergillus* colonisation ($n = 89$)	P^a
Age (years)	54 (51–63)	61 (50–69)	61 (51–69)	66 (47–72)	0.186
APACHE II score	28 (21–30)	28 (20–31)	28 (19–34)	24 (20–29)	0.021
Neutropenia	3 (17.7)	8 (12.1)	11 (13.3)	2 (2.2)	0.008
Hemodynamic instability	17 (100)	49 (74.2)	74 (89.2)	58 (65.2)	< 0.001
Acute renal failure	10 (58.8)	23 (34.9)	33 (39.8)	23 (25.8)	0.073
Acute respiratory failure	17 (100)	63 (95.5)	80 (96.4)	77 (86.5)	0.029
Duration of mechanical ventilation prior to first positive culture (days)	2 (1–8)	4 (1–9)	3 (1–8)	3 (1–7.5)	0.690
Duration of mechanical ventilation (days)	11 (6–24)	15 (6–32)	13 (5–29)	9 (3–21)	0.031
Length of ICU stay prior to first positive culture (days)	2 (1–8)	4 (1–9)	4 (1–8)	5 (1–9)	0.396
Length of ICU stay (days)	11 (7–24)	15 (7–34)	14 (7–31)	13 (6–25)	0.383
Number of cultures positive for *Aspergillus* spp.	2 (2–3.5)	2 (2–3)	2 (2–3)	1 (1–2)	< 0.001
Number of patients examined with BAL	12 (70.6)	49 (74.2)	61 (73.5)	29 (32.6)	< 0.001
28-days mortality	15 (88.2)	44 (66.7)	59 (49.0)	26 (23.1)	< 0.001
In-hospital mortality	16 (94.1)	48 (72.7)	64 (77.1)	36 (40.4)	< 0.001

Expérience allemande

(von Eiff, Respiration, 1995)

- Période: 1987 à 1992
- 33 patients immunodéprimés avec API (dont 27 pts hématologiques)
- si traitement antifungique endéans les 10 jours: mortalité 41%
- si traitement antifungique supérieur à 10 jours: mortalité 90%

REDUIRE LE DELAI

- Traitement précoce dès suspicion API chez un patient à risque

- « Nouveaux » patients à risque (Stuck, Rev Infect Dis,1989)
  corticothérapie > 10 mg/j prednisone
  > 700 mg dose cumulative prednisone

- Méthodes diagnostiques:
  - antigénémie
  - scanner thoracique
  - fibroscopie bronchique

METHODES DIAGNOSTIQUES

Antigénémie: expérience de la KUL

(Maertens, J Clin Microbiol, 1999)

- 186 pts hématologiques; ELISA 2x/sem
- 71 pts autopsiés: 27 AI prouvée, 44 AI possible
- sensibilité 93%, spécificité 95%
- VPP 93%, VPN 95%
- Antigénémie positive 6 j avant suspicion clinique

METHODES DIAGNOSTIQUES

Antigénémie: MAIS

- D'autres études moins favorables, avec une sensibilité de moins de 50%
- et pas d'avantage sur les signes cliniques et Rx
- Méta-analyse: sens.: 61-71%; spéc.: 89-93%
- Intérêt d'un suivi prospectif, stt si augmentation
- Attention aux faux positifs: Augmentin, Tazocin, Nourriture, endoxan, autres champignons
- Données plus limités dans les autres populations de patients
- Réduction de la mortalité?
- PCR et β-D-glucan: en cours de validation

Herbrecht JCO 2002; Viscoli CID 2004; Ulusakarya Hematology J 2000; Williamson JCP 2000; Boutboul Clin Infect Dis 2002; 34: 939–943; J Clin Microbiol. 2012;50:2330-6

METHODES DIAGNOSTIQUES

CHU Dinant Godinne UCL NAMUR

Fibroscopie bronchique:

- LBA: sensibilité: ~ 50%
  spécificité: ~ 90%
  Galactomannan: sens: 93%, spec 87%
  PCR: prometteurs

- AET: sensibilité: 46 à 77%
  spécificité: ? (colonisation?)

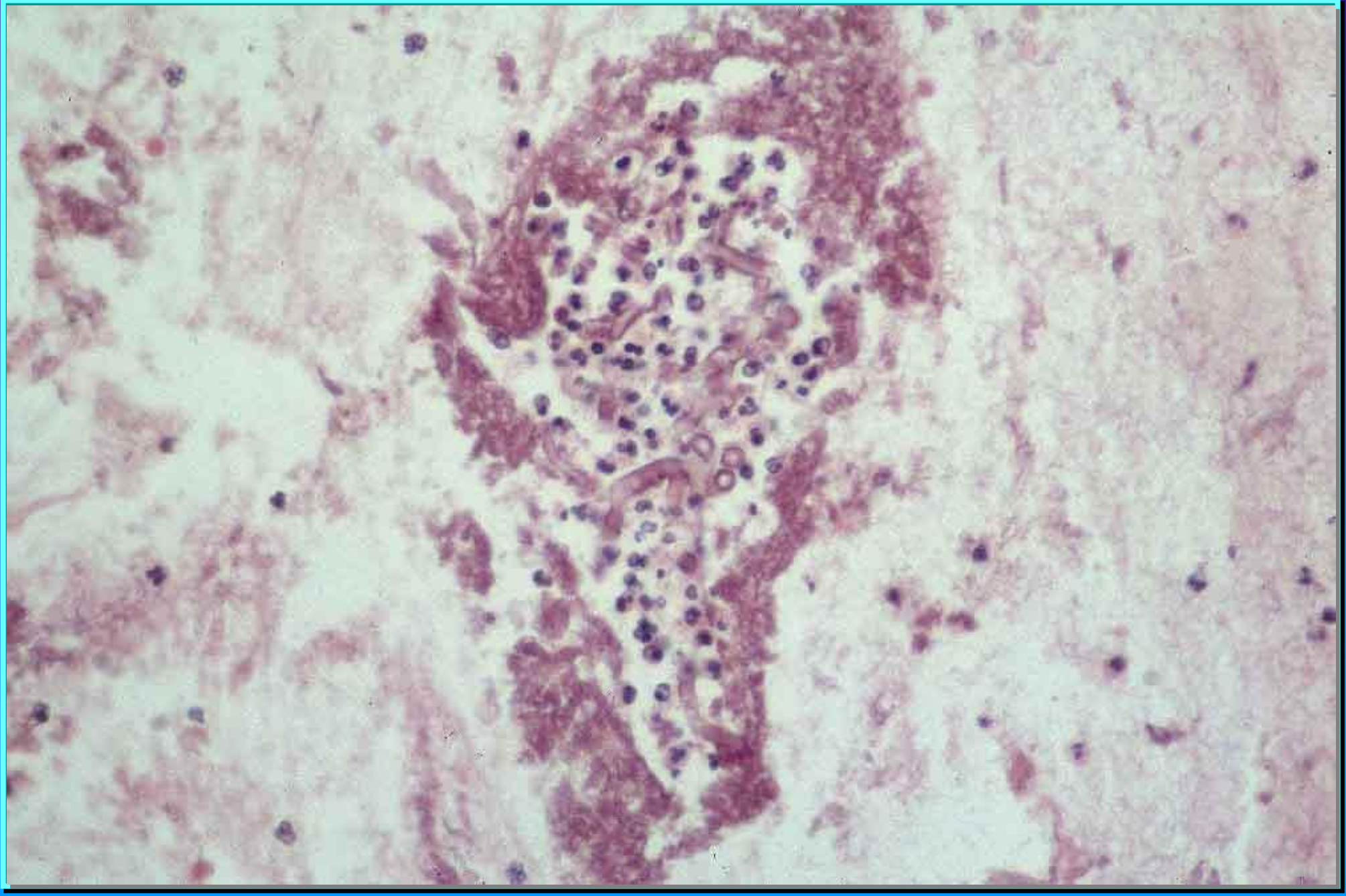

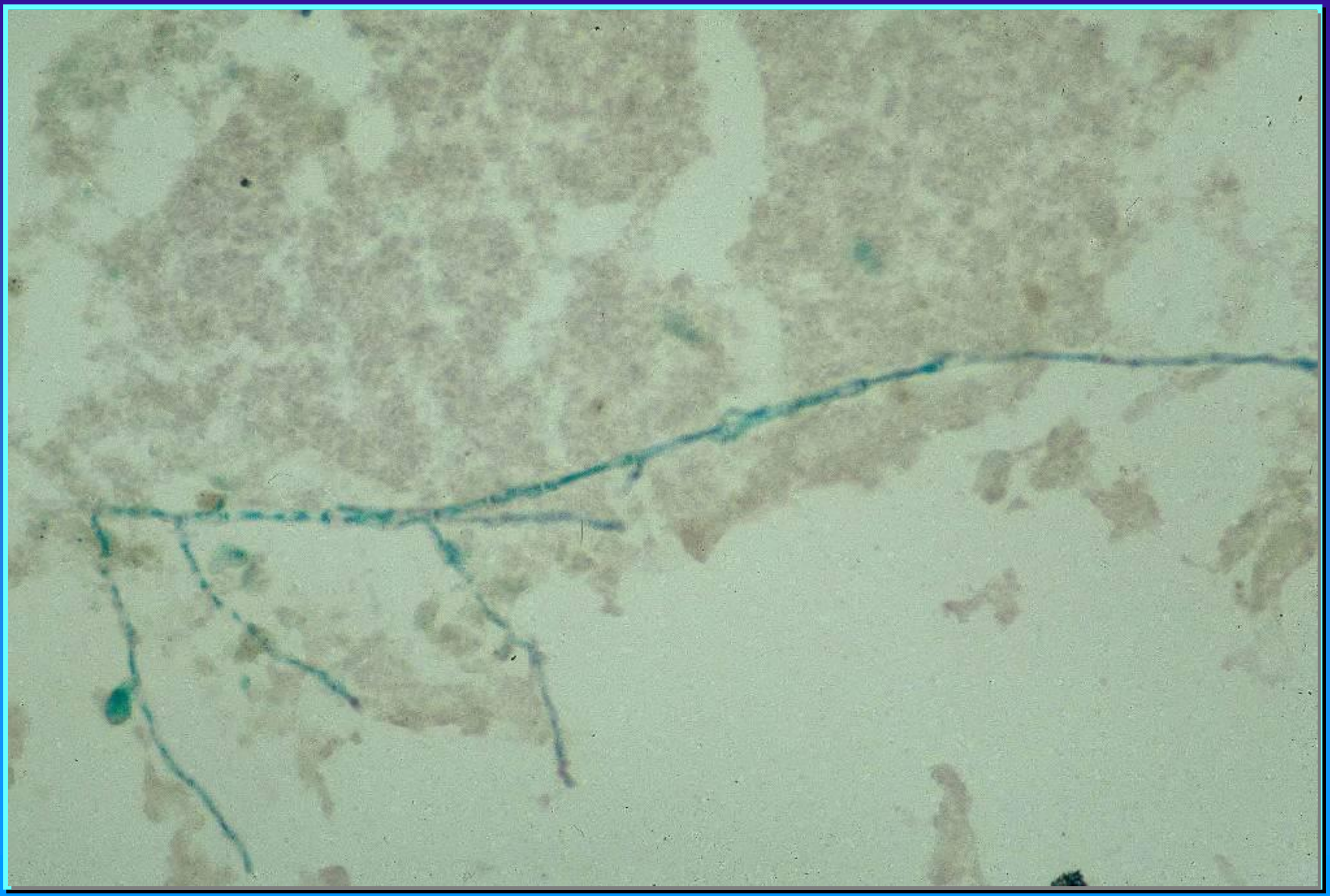

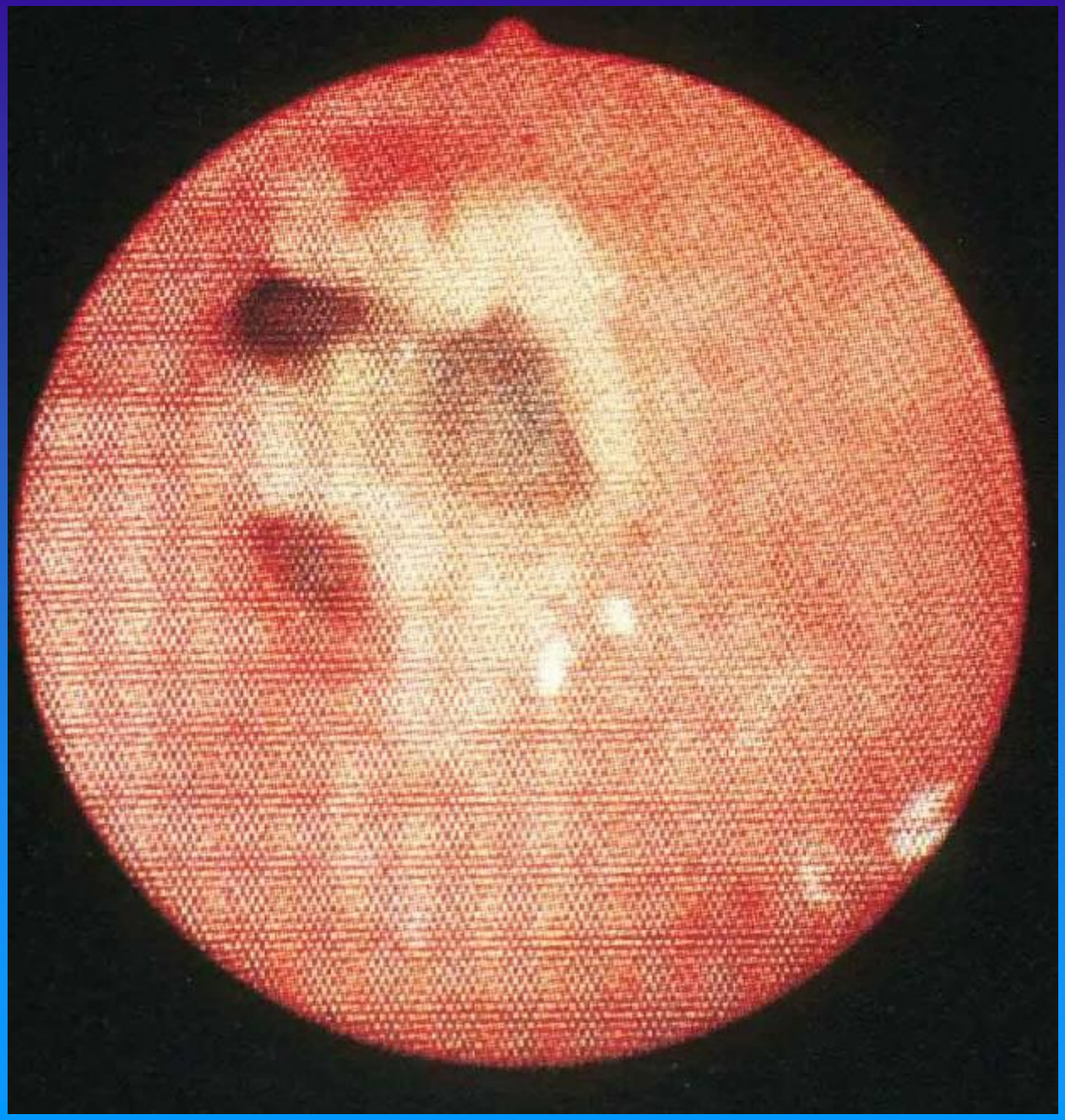

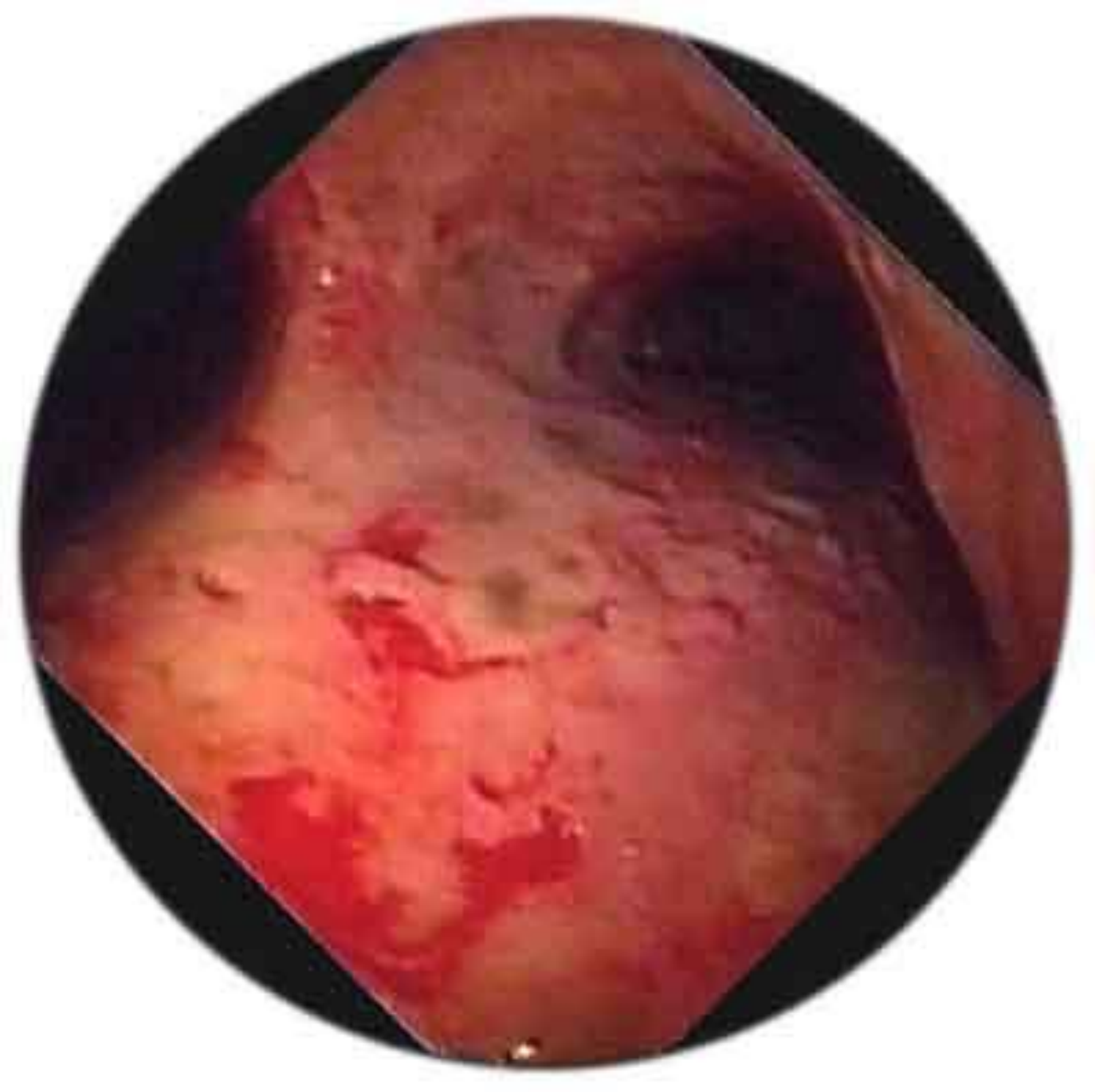

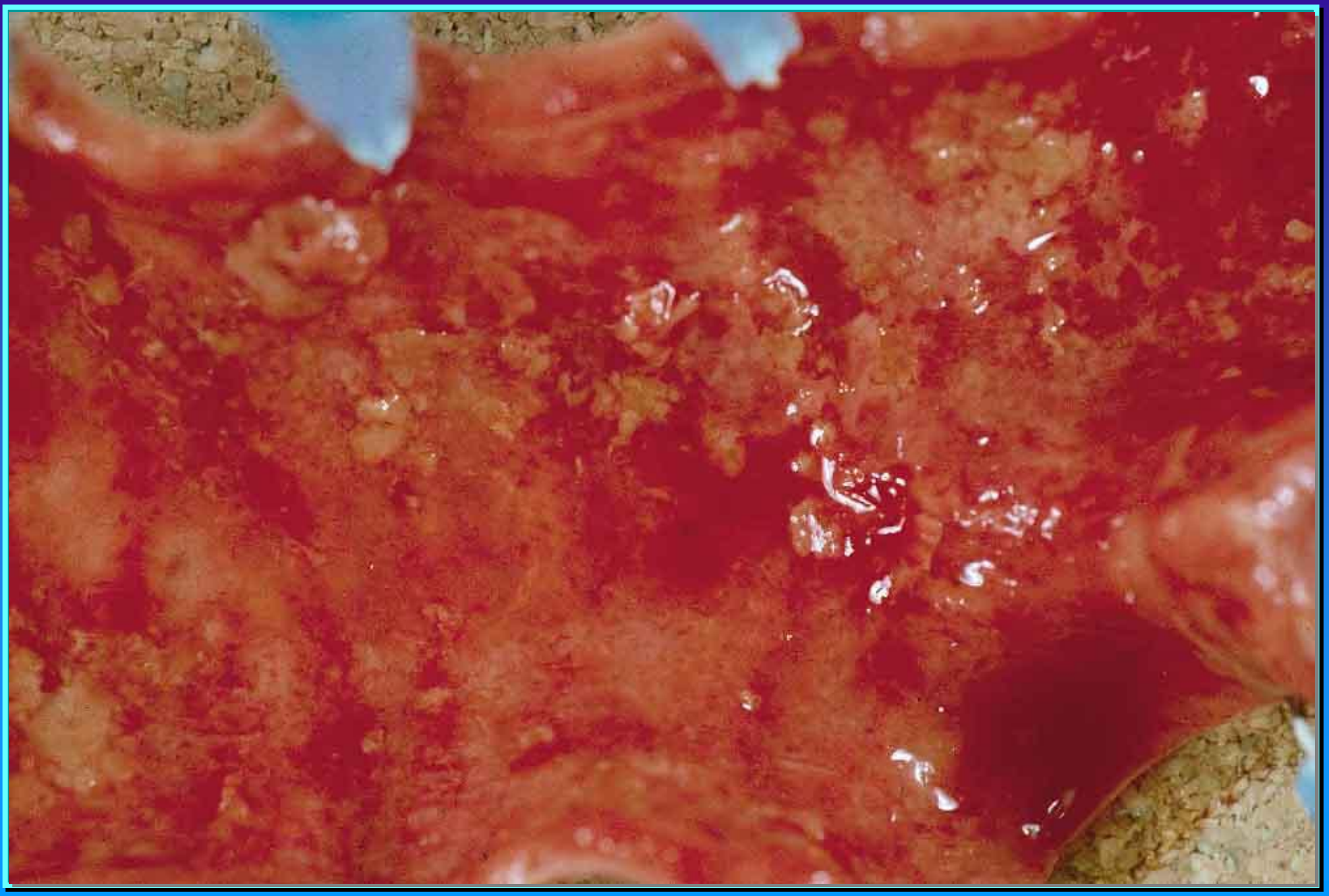

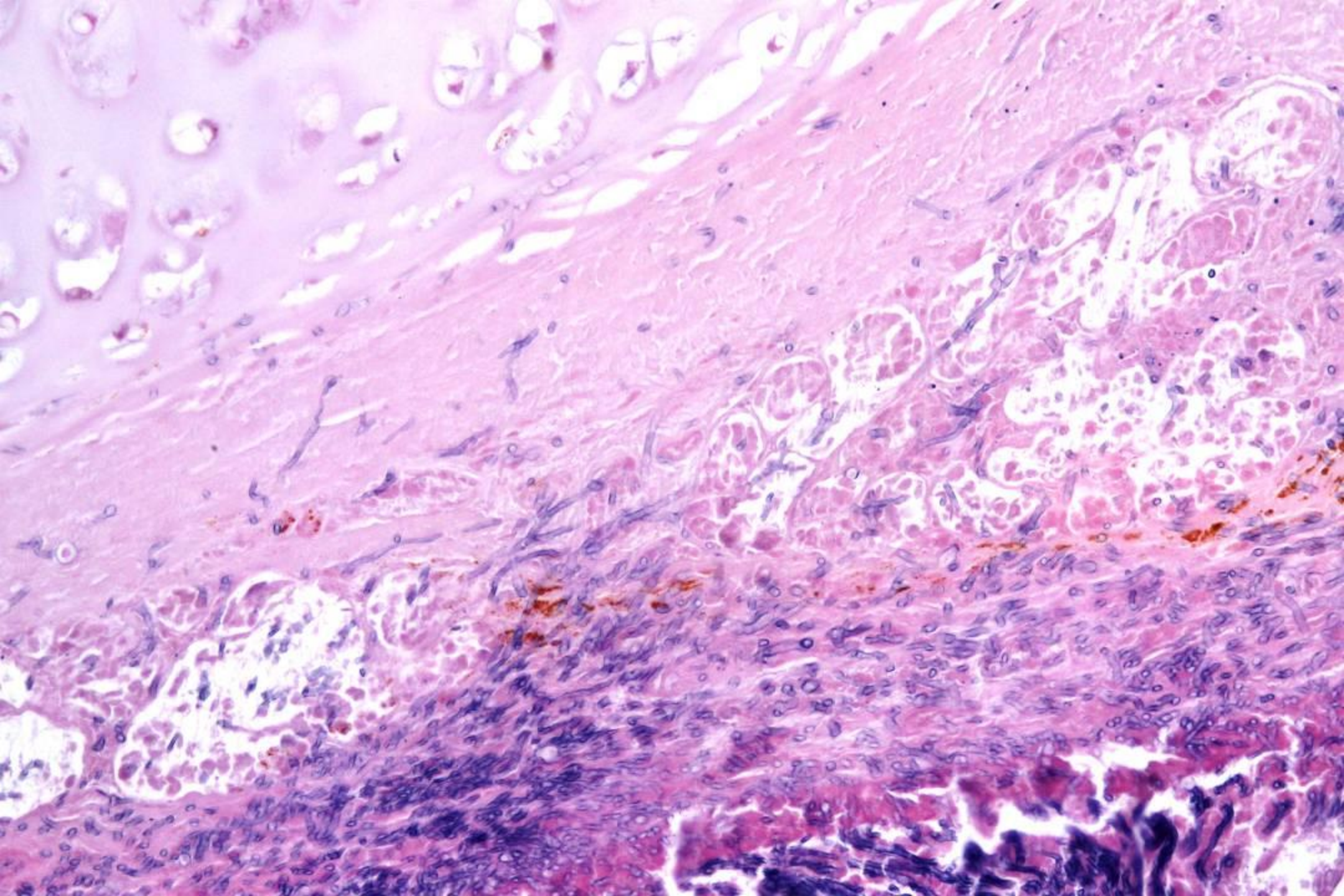

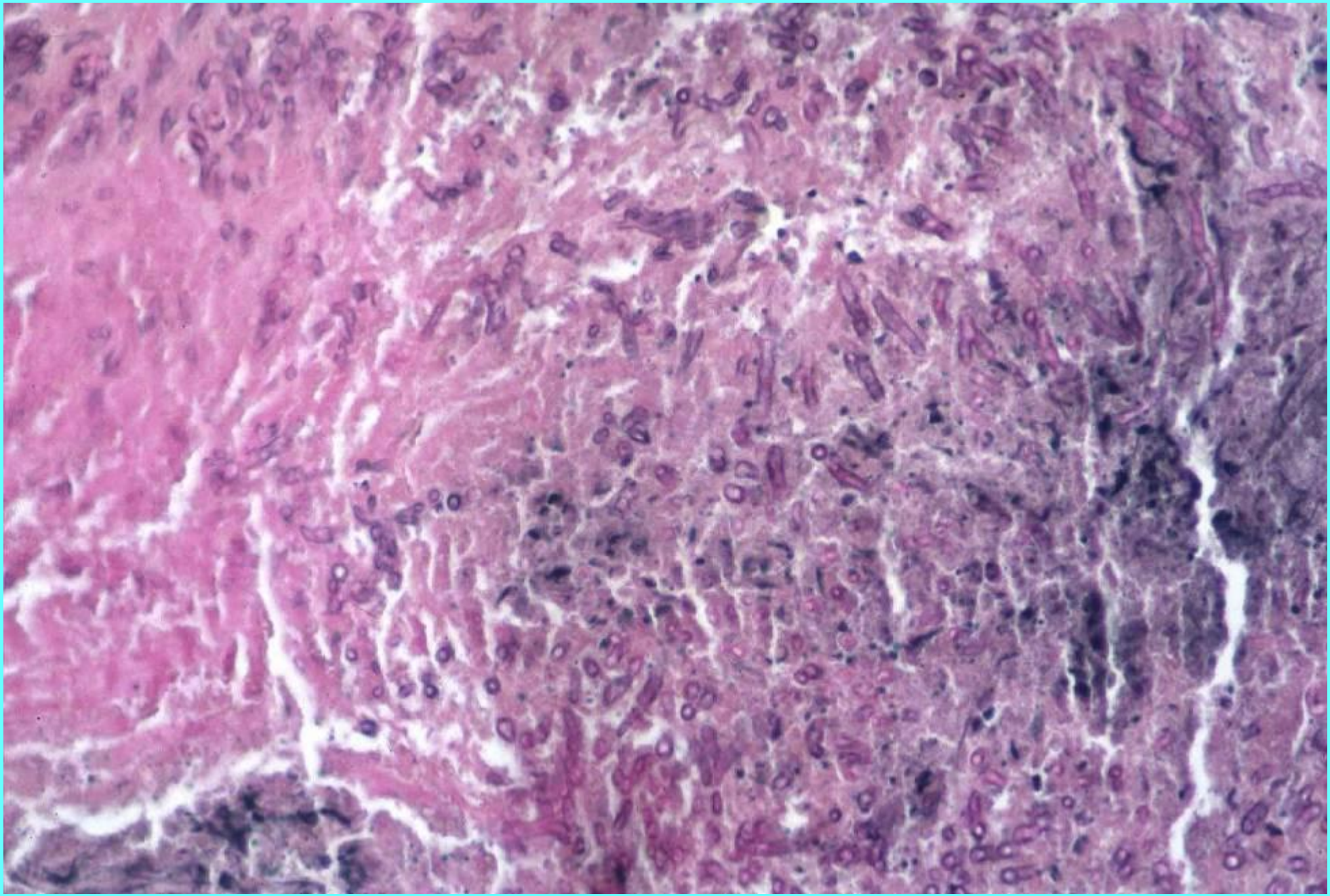

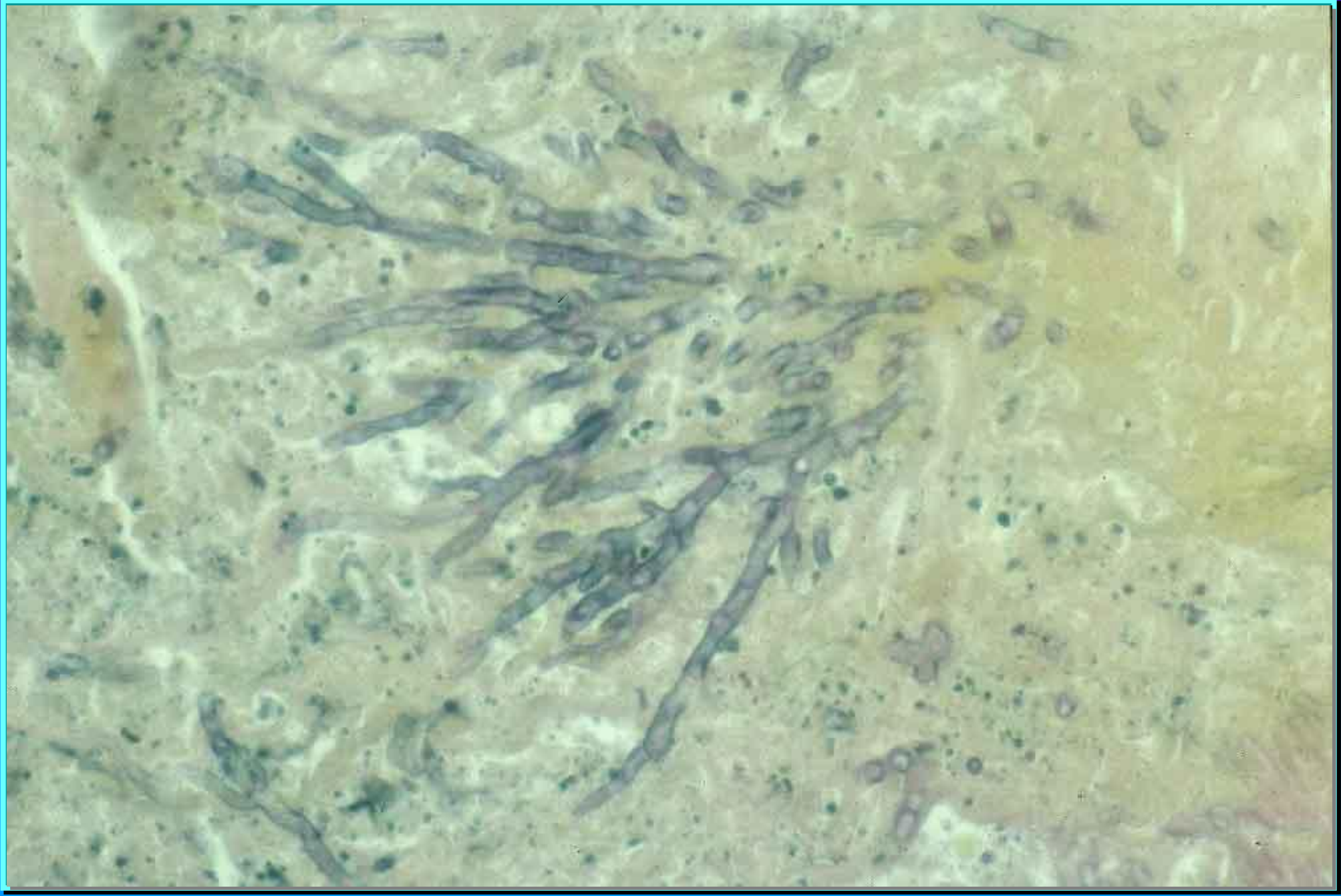

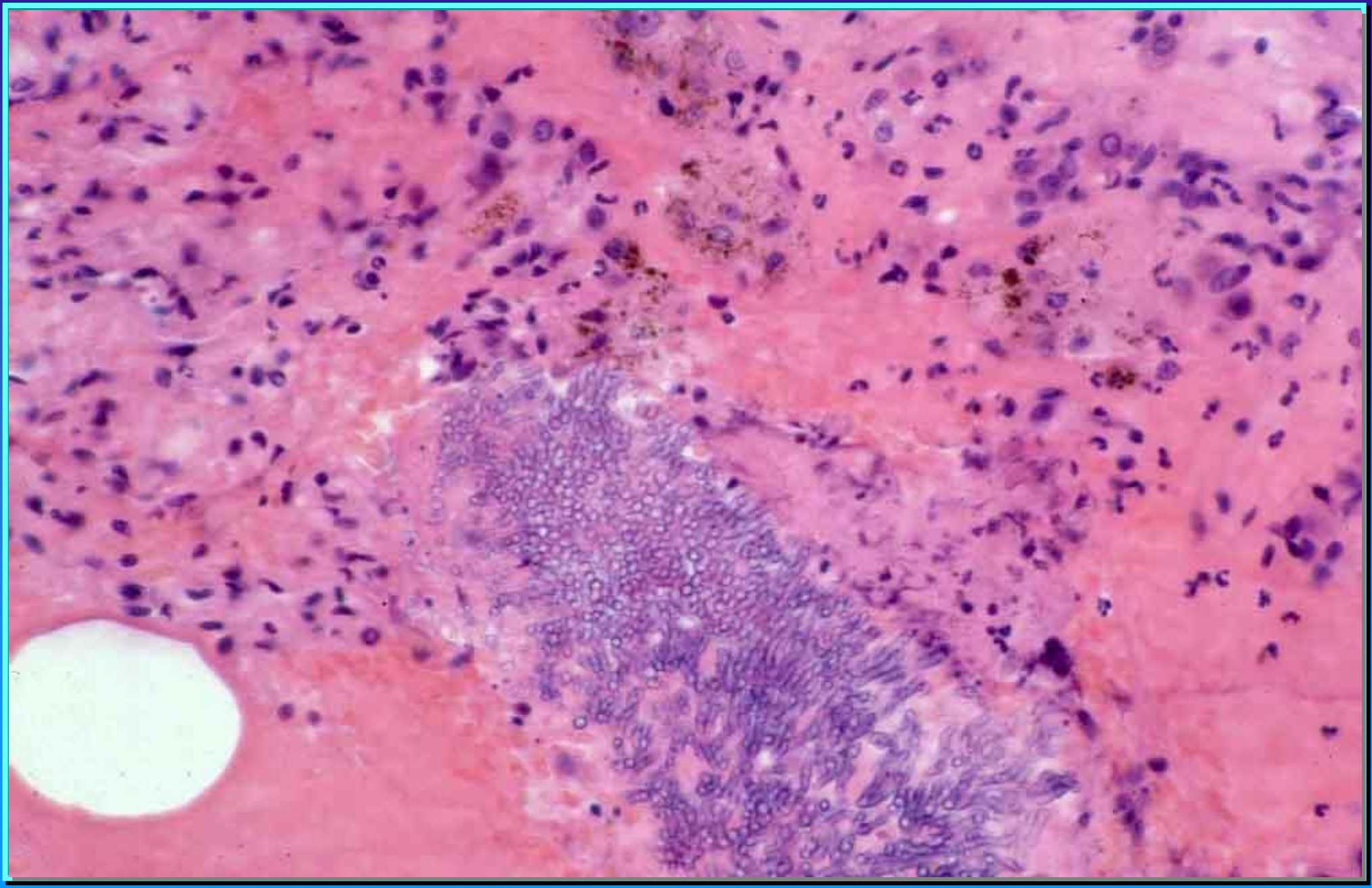

RADIOLOGIE

Rx Thorax:

- Hétérogène: - lésion cunéiforme à raccord pleural

  - lésion(s) nodulaire(s)

  - nodule(s) ou lésion(s) excavée(s)

  - consolidation aspécifique
- Normale au stade précoce

RADIOLOGIE

Scanner thoracique:

Chez les patients neutropéniques:

- Signe du halo
- Signe du croissant aérique

SCANNER THORACIQUE

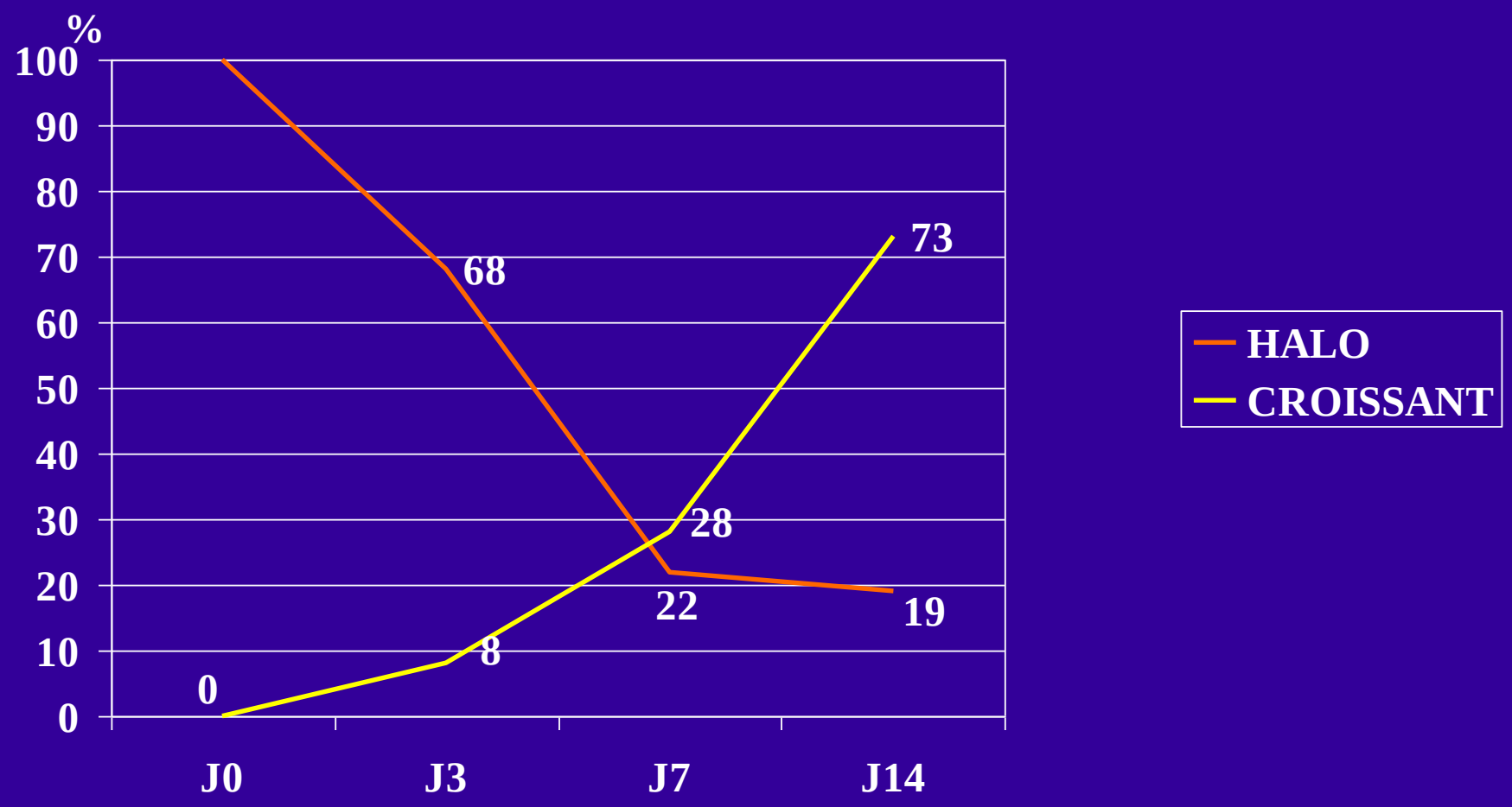

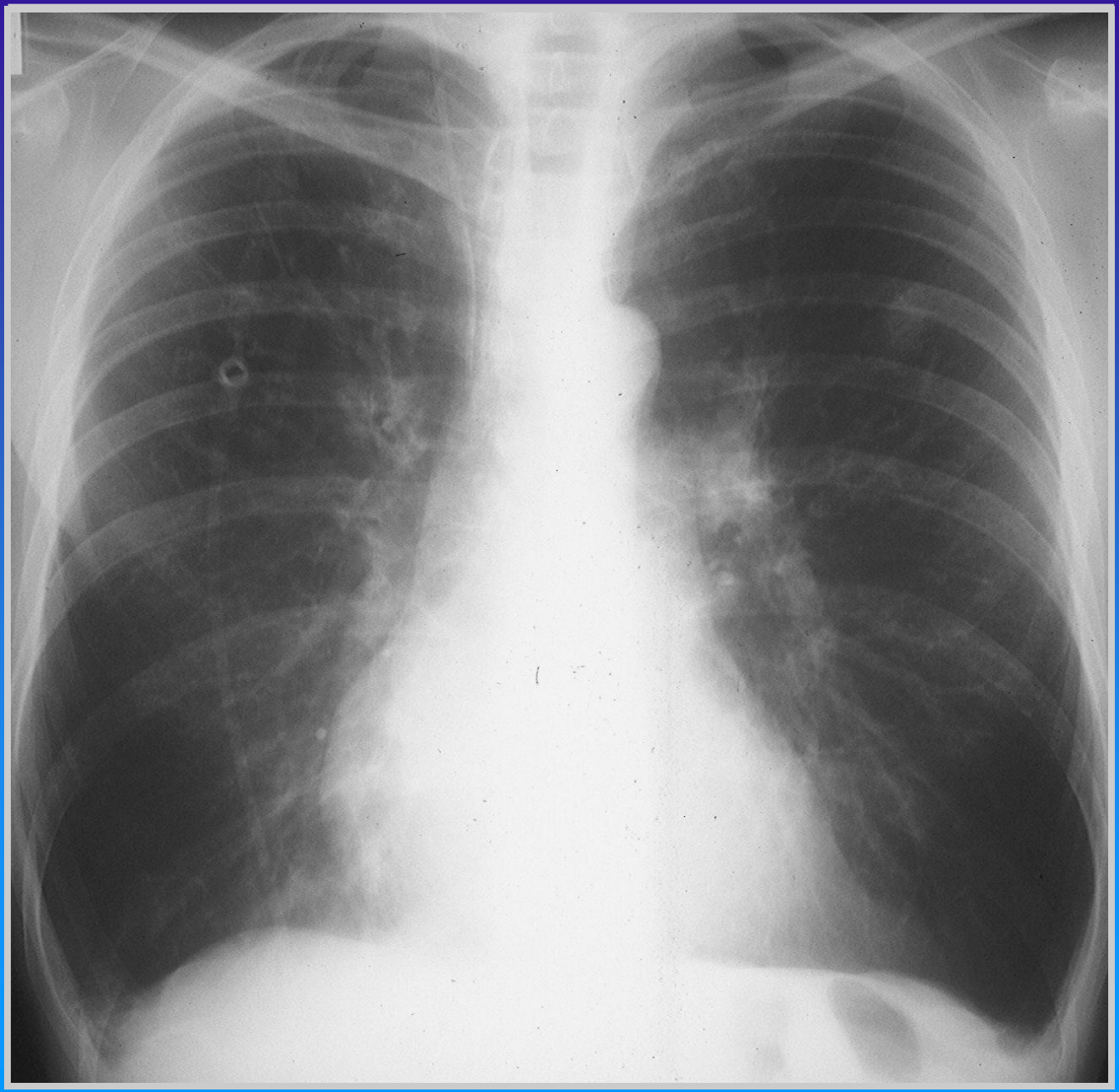

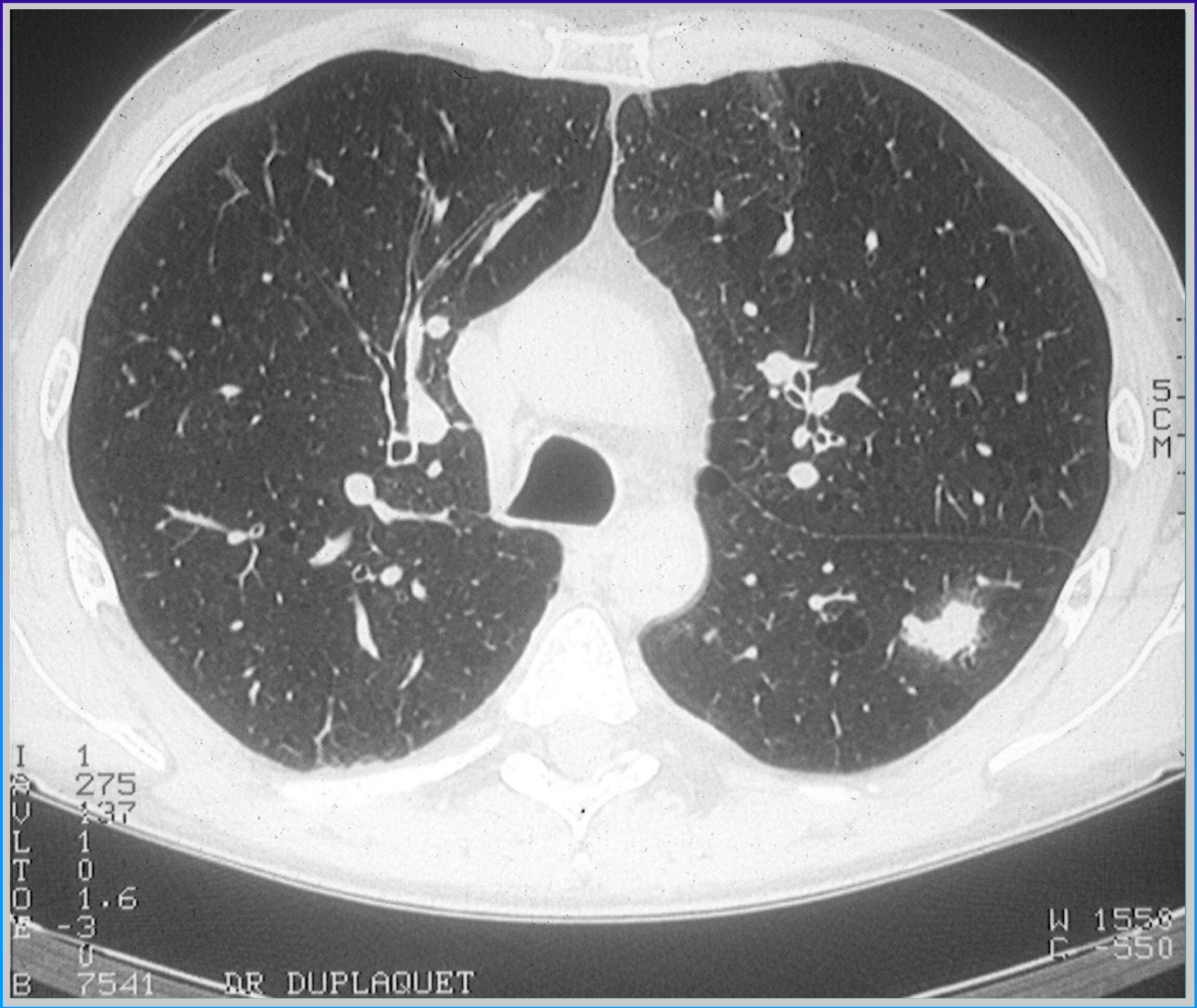
5
CM
I 1
275
137
1
0
1.6
-3
0
B 7541
DR DUPLAQUET
W 1550
C -550

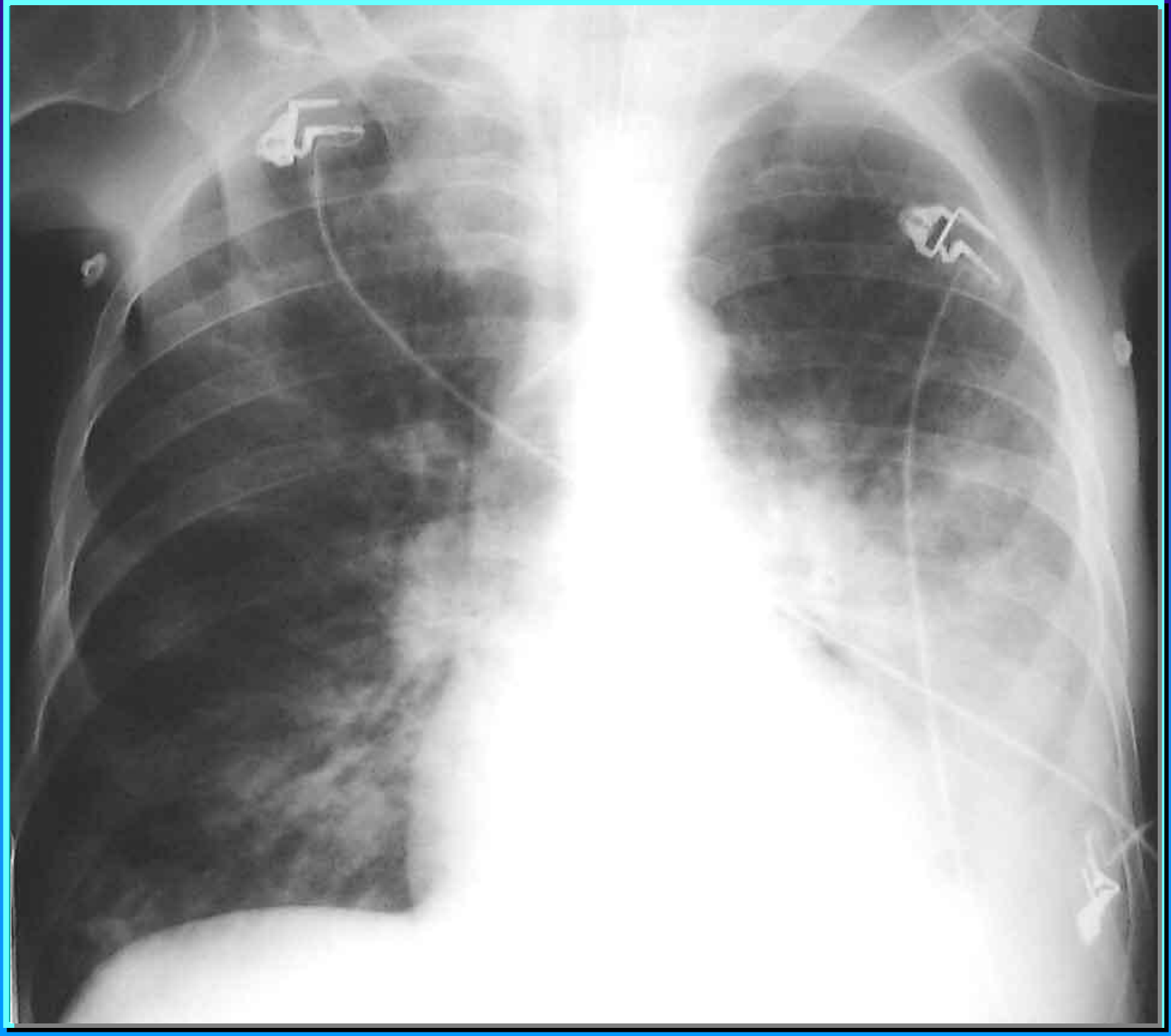

1
165
120
8/12
0
1.6

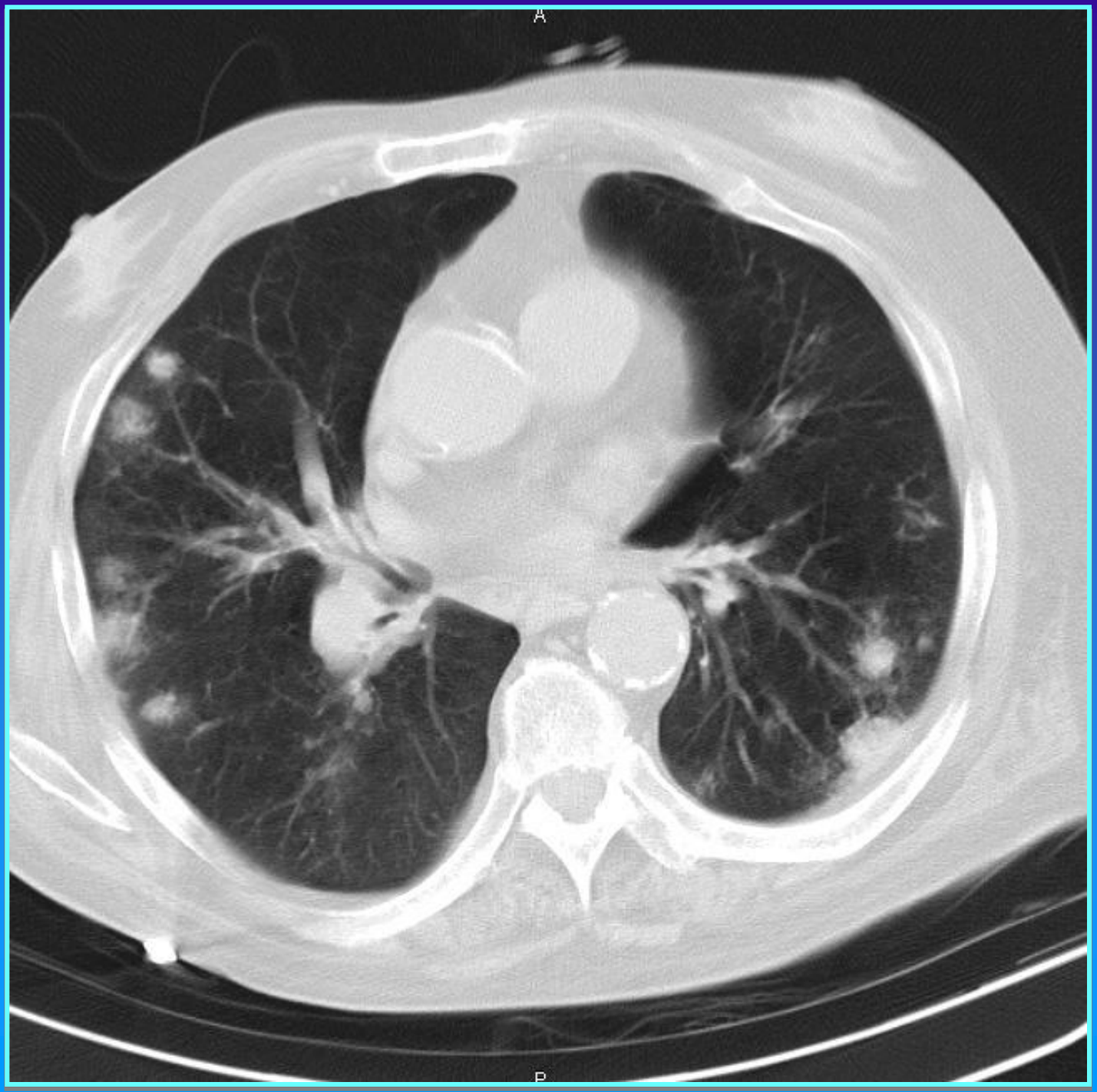
A
P

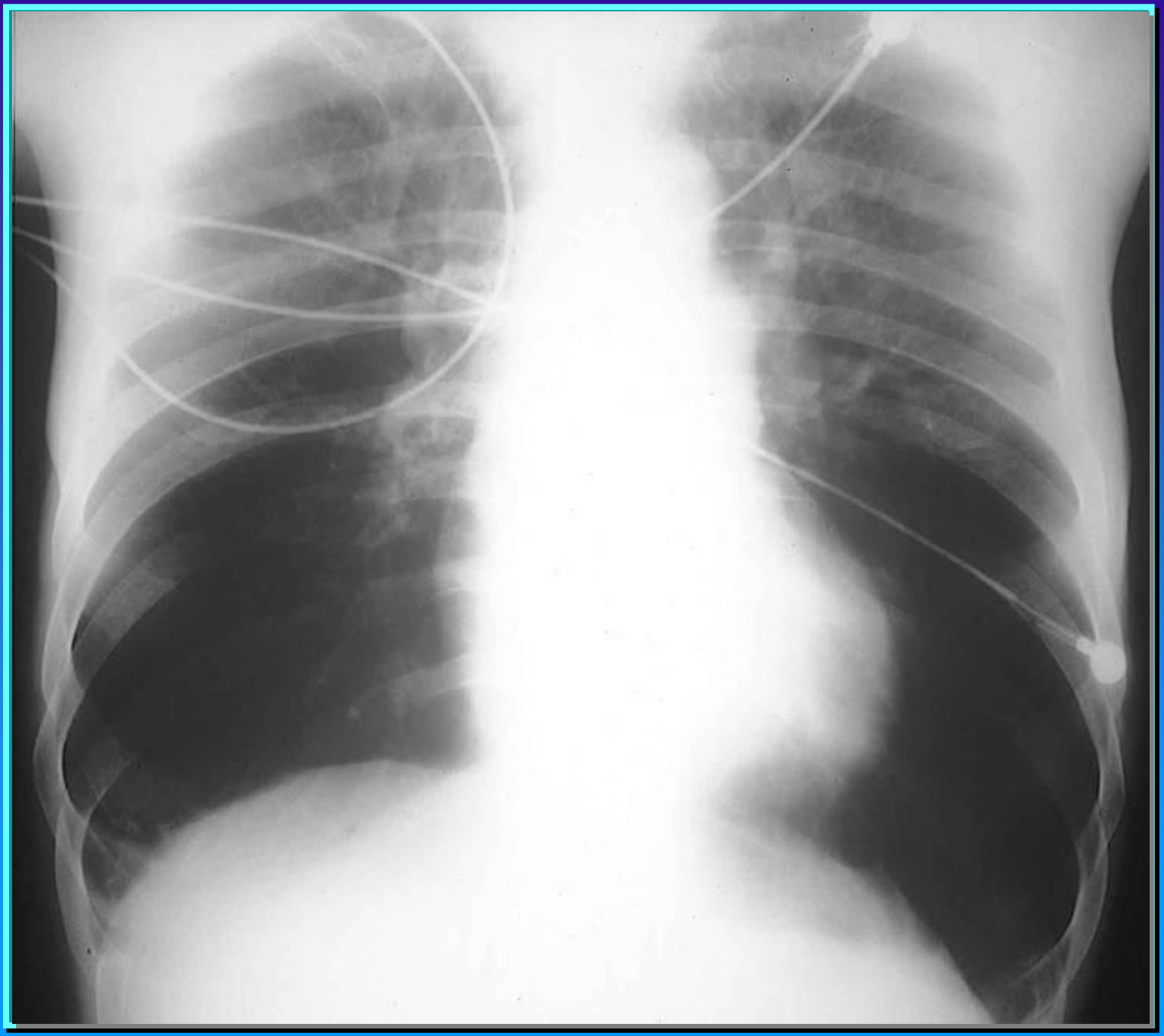

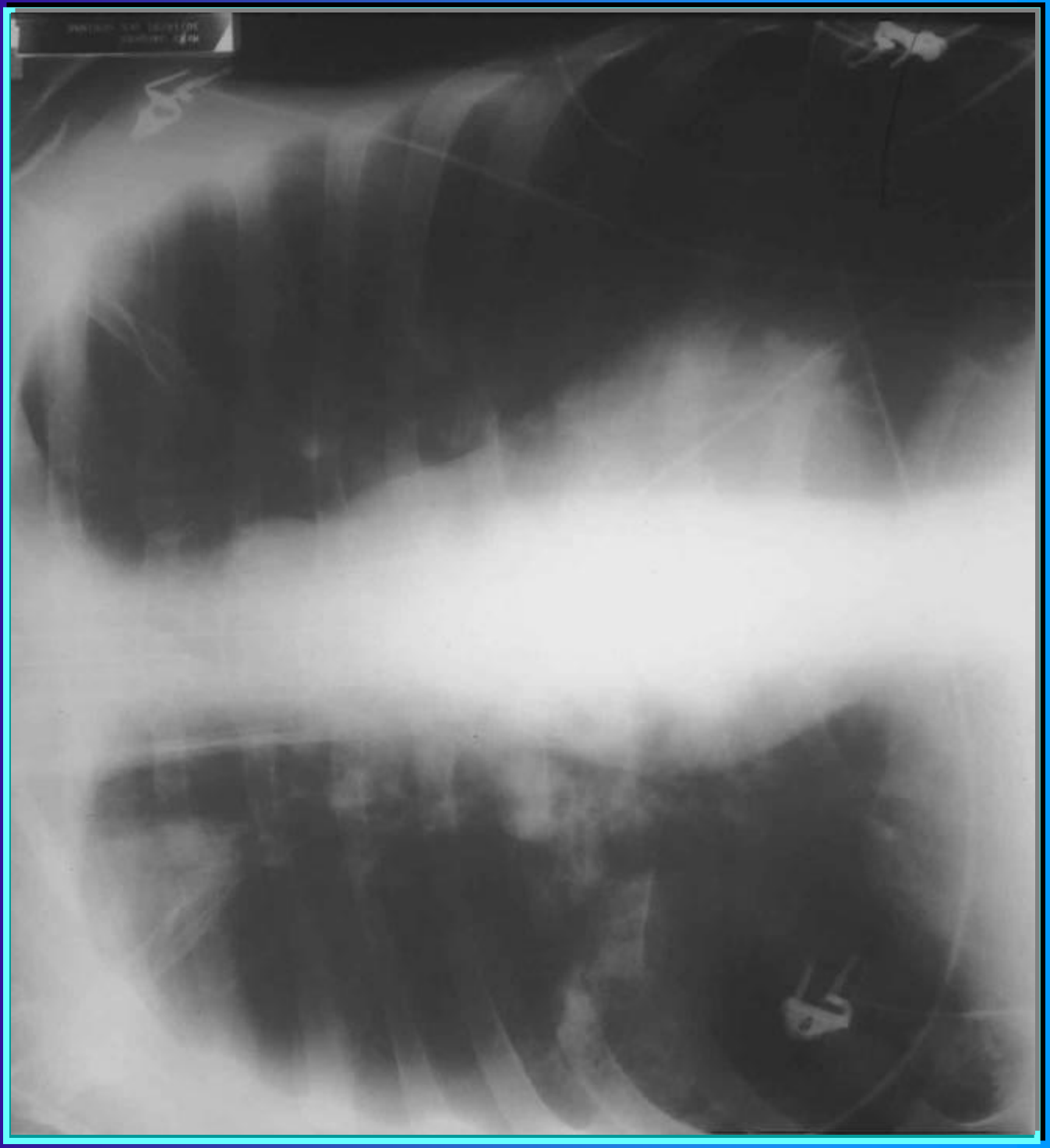

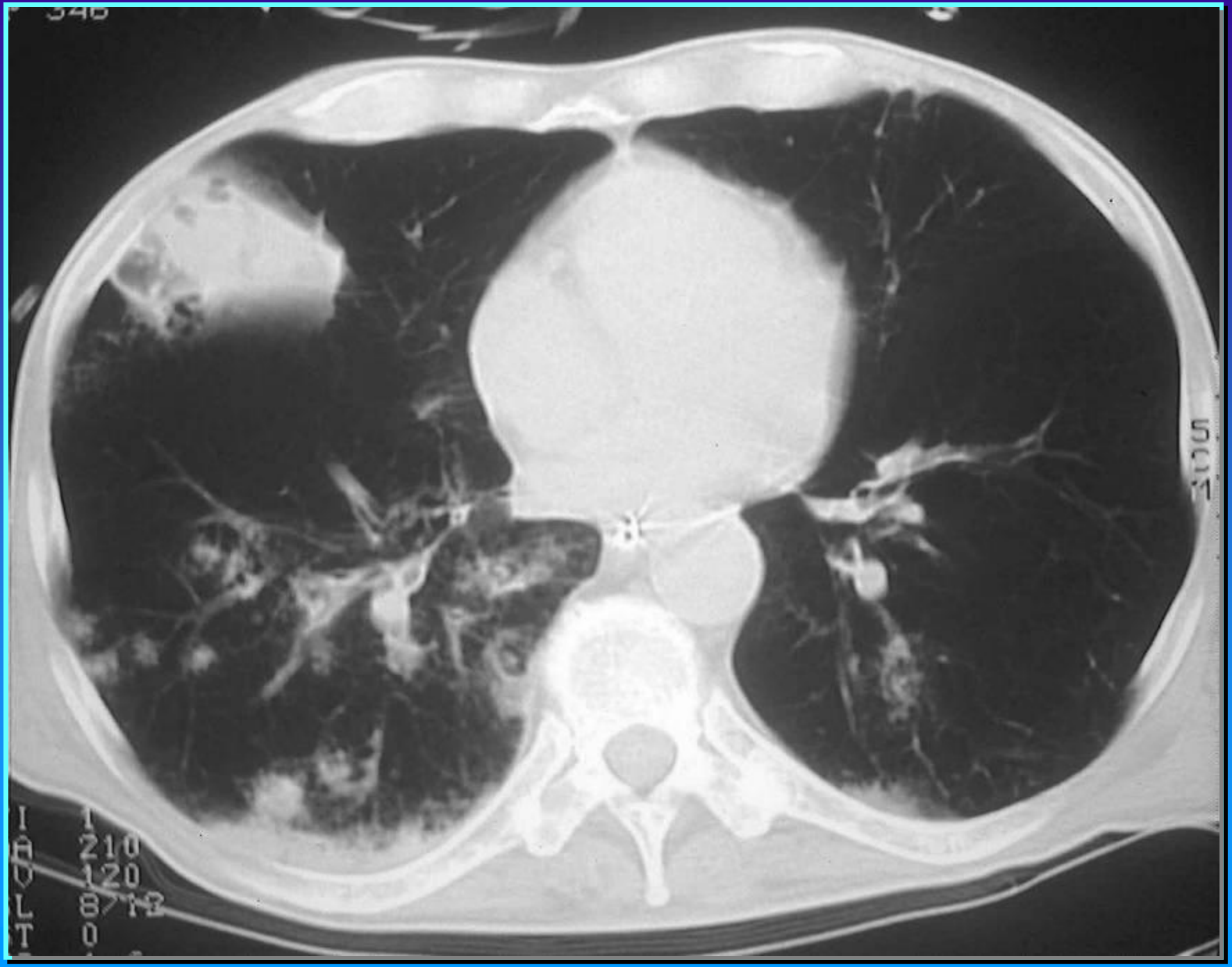
I 1
A 210
W 120
L 8/13
T 0

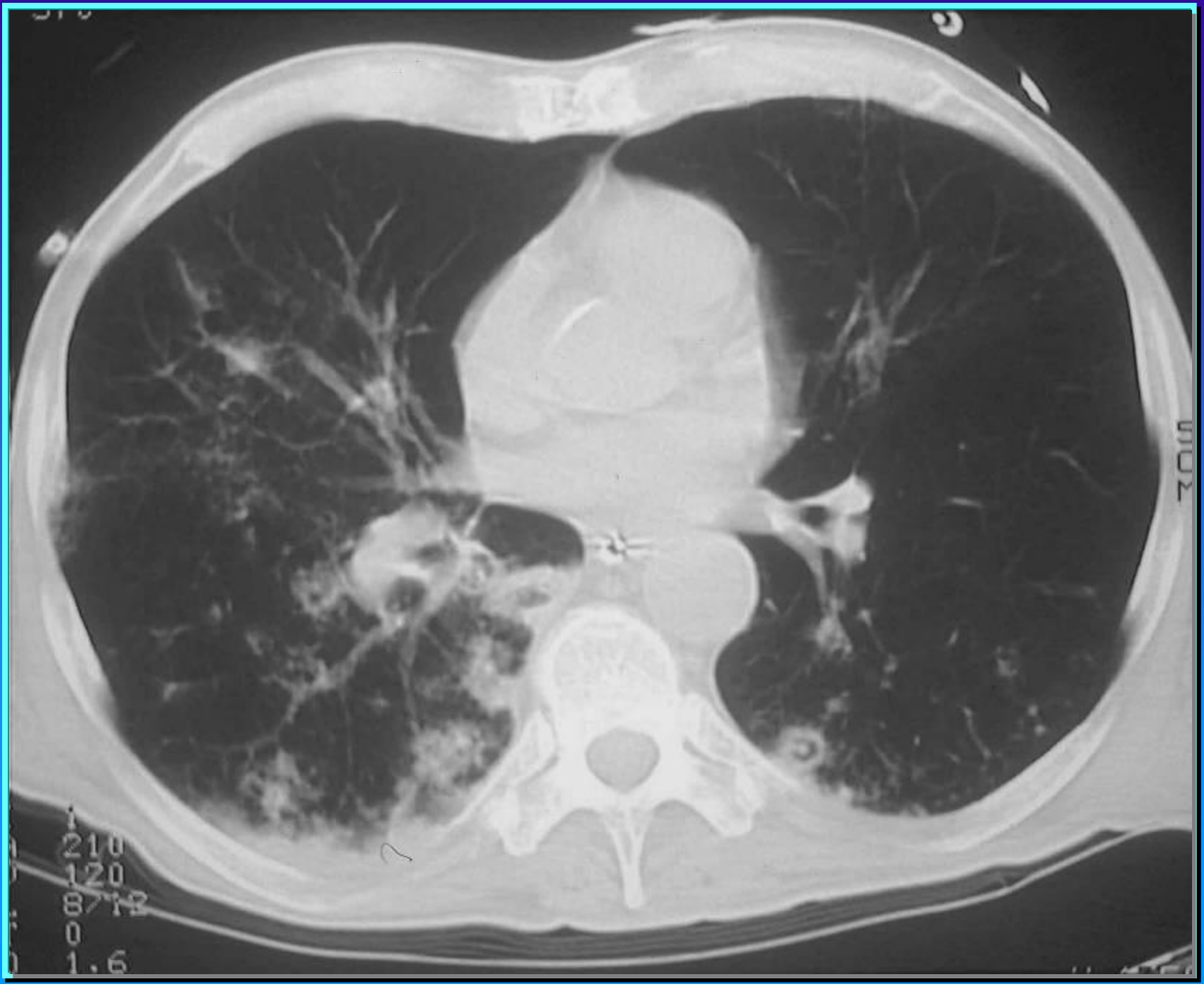
1
210
120
8/12
0
1.6

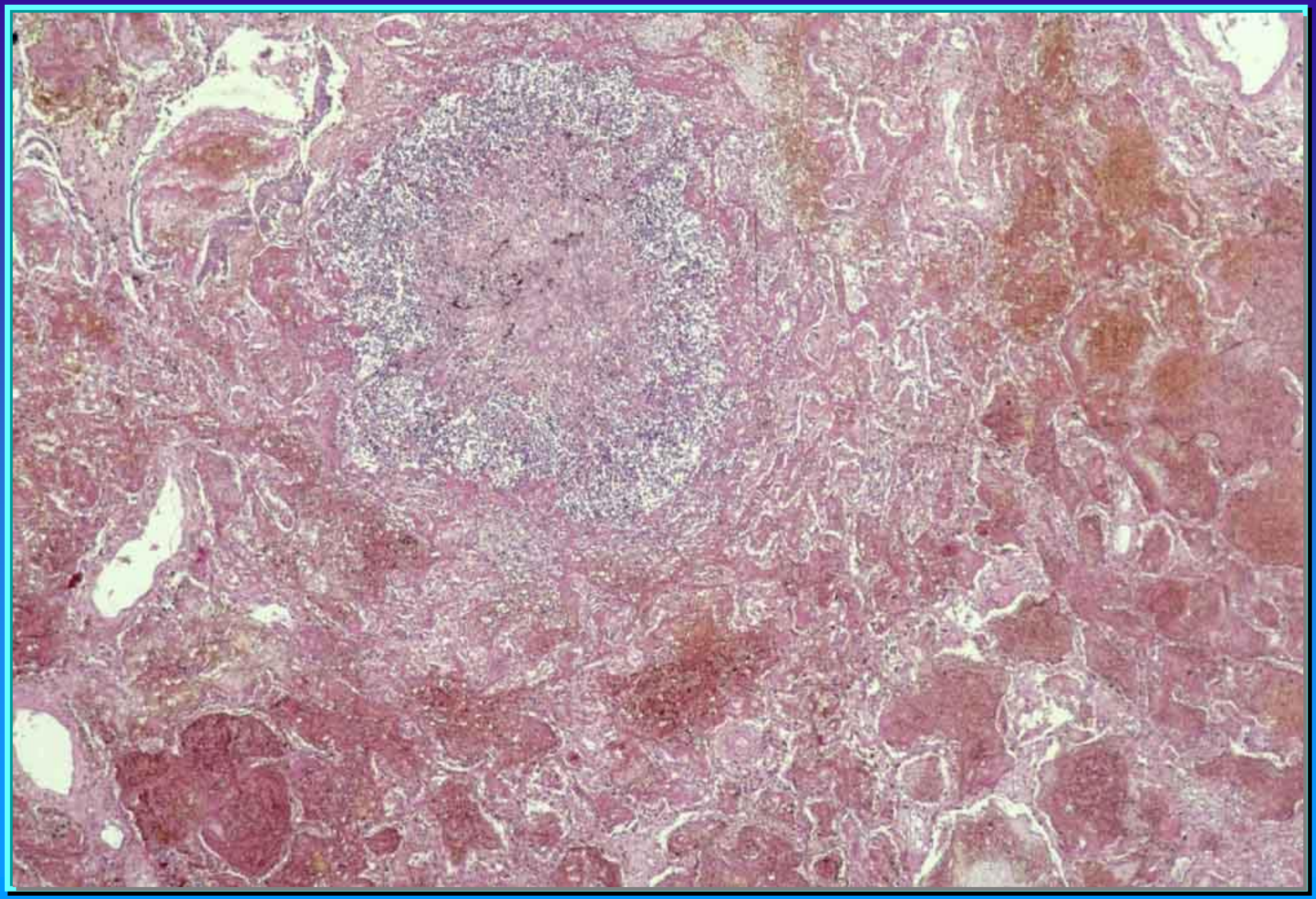

METHODES DIAGNOSTIQUES

Scanner: **expérience dijonnaise** (Caillot, Med Mal Infect, 1998)

- **Etude prospective**
- **Période:** **janvier 88 à novembre 96**
- **Population:** **577 pts : hémopathie maligne**
  260 greffes de moelle
- **Démarche diagnostique:**
  1. **Scanner thoracique**
  2. **Antigènémie aspergillaire**
  3. **Fibroscopie bronchique**

METHODES DIAGNOSTIQUES

Scanner: **expérience dijonnaise** (Caillot, Med Mal Infect, 1998)

- **45 pts atteints d 'API .**
- **6 pts greffés médullaires dont 4 autologues**
- **Délai diagnostique: 1.8 ± 1.3 j vs 7 ± 5.5 j**
- **Traitement:** - antifungique
  - chirurgie: 18 pts
- **Mortalité: 21% versus 50%**

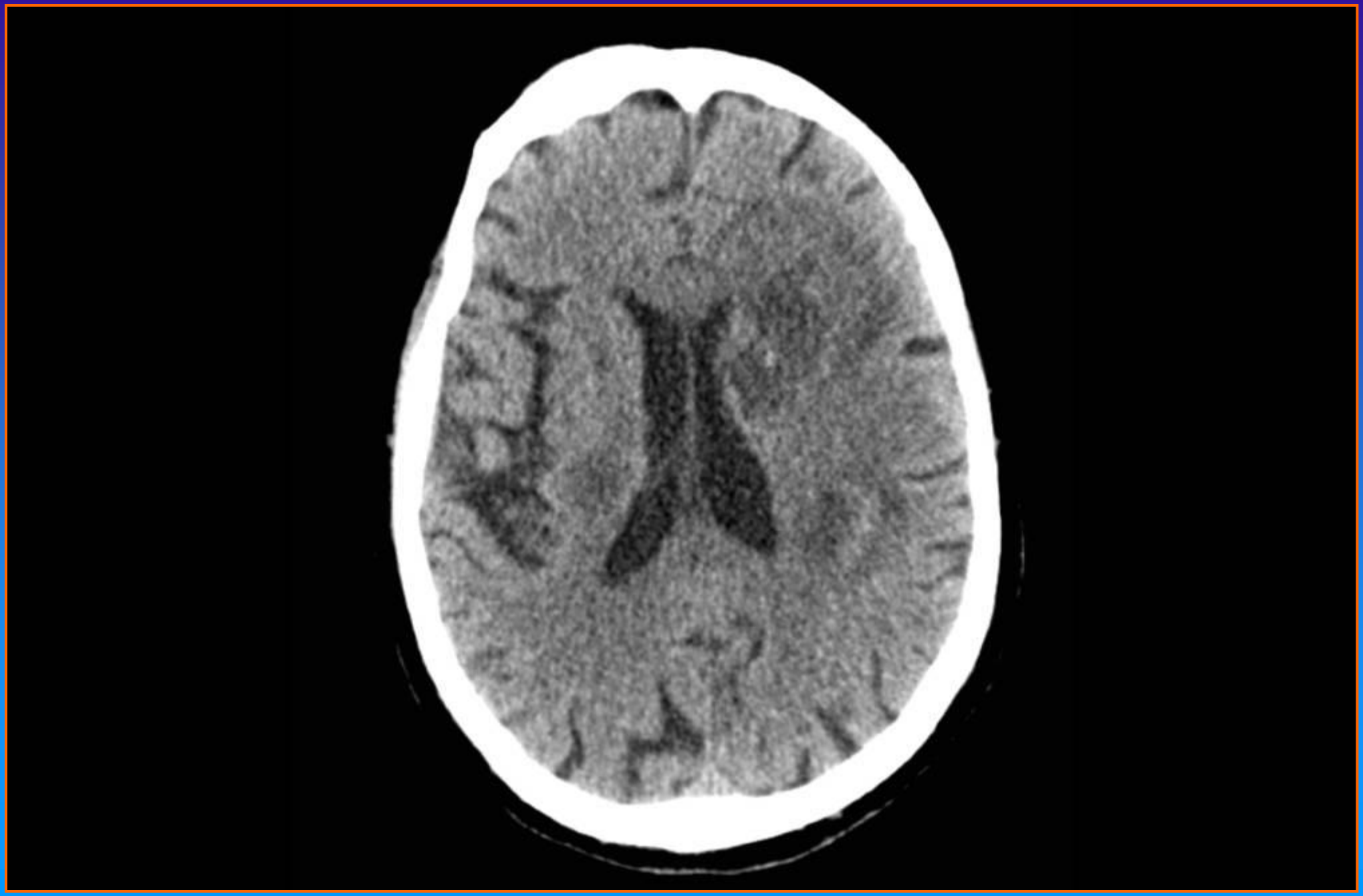

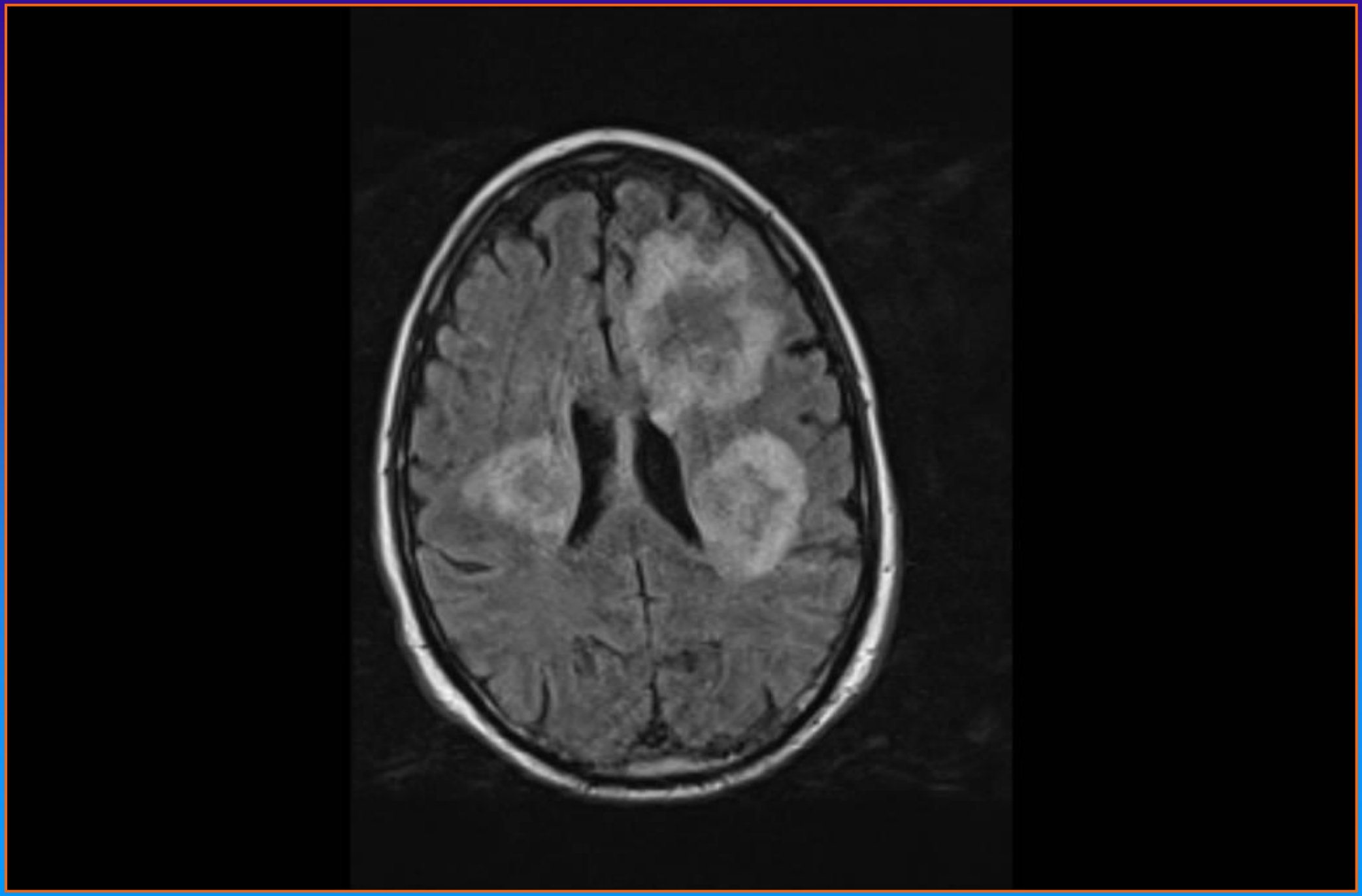

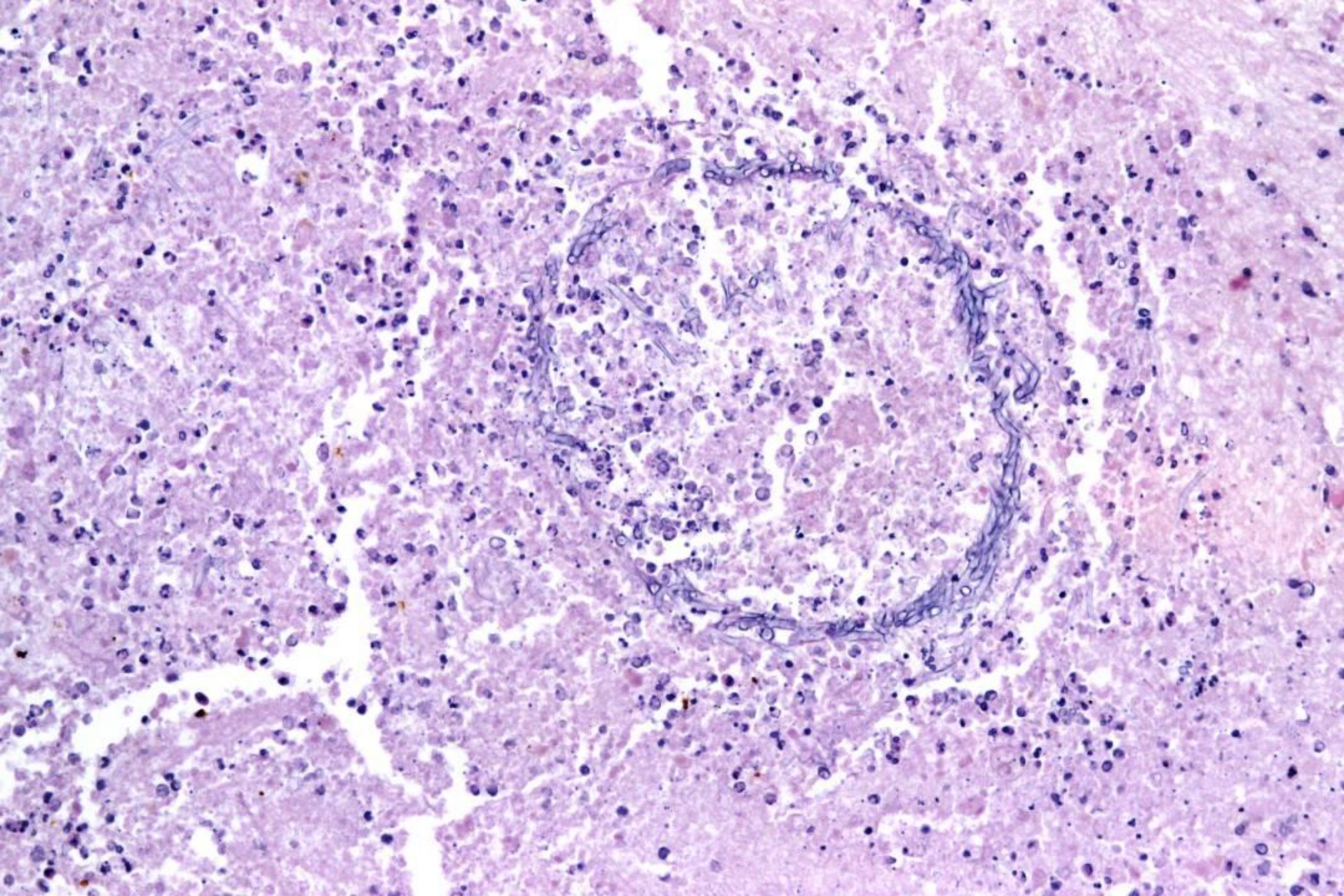

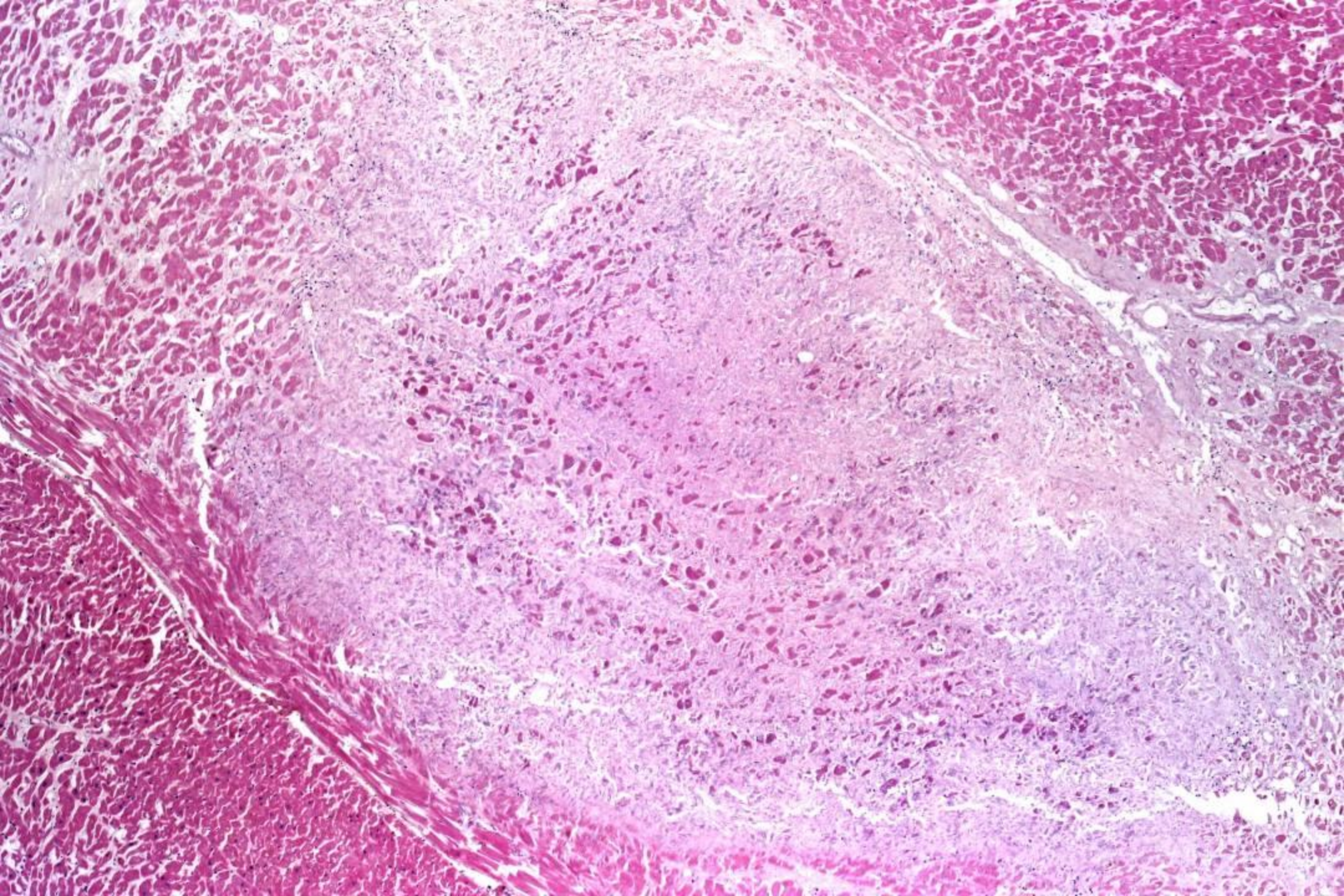

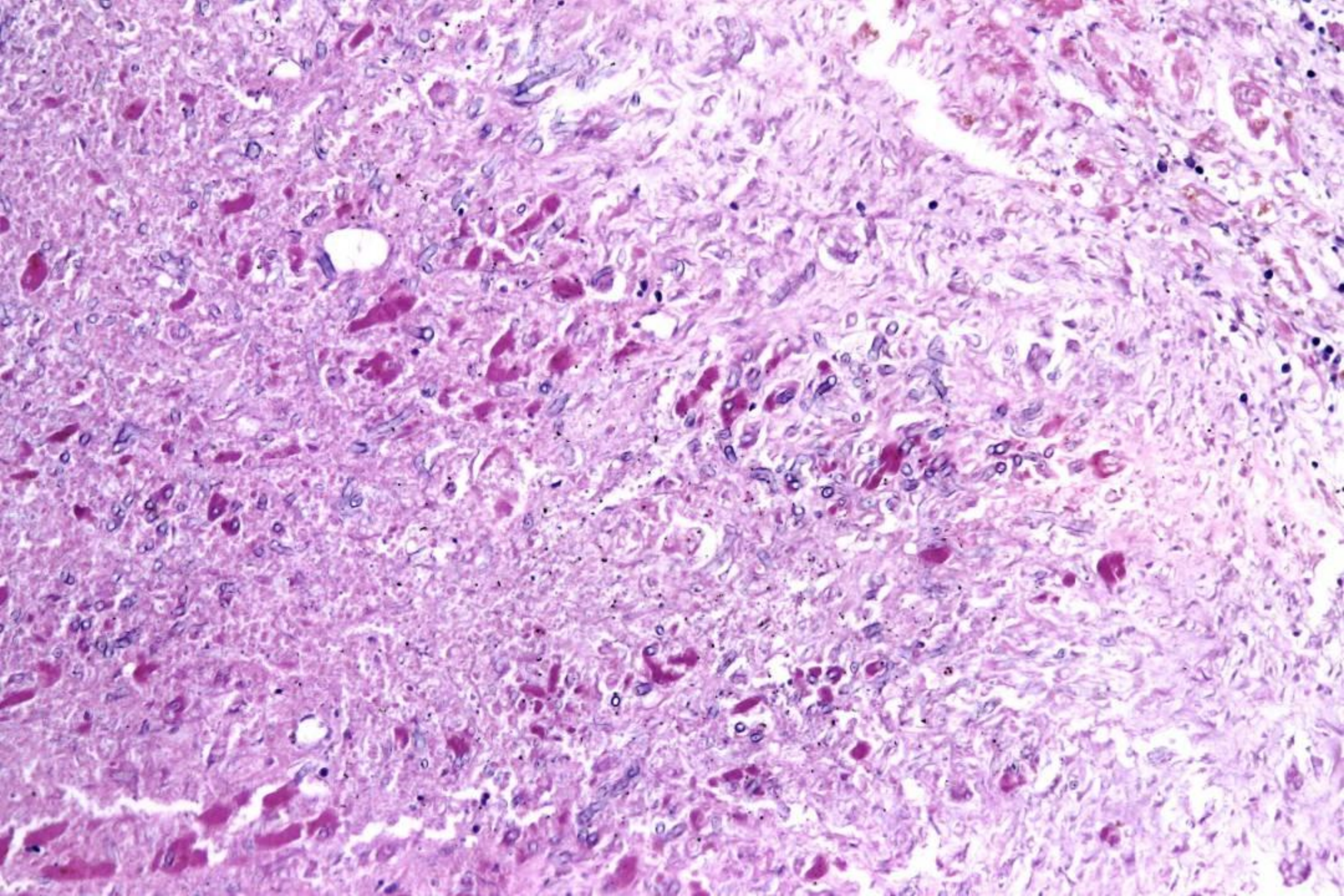

TRAITEMENT HISTORIQUE

- <u>Médical:</u> 1. Amphotéricine B (infusion continue?)
  1 à 1.5 mg/kg/j sans adaptation si IR
  2. Ambisome 3mg/kg/j (pfs 5mg/kg/j)
  Abelcet 5 mg/kg/j
  meilleure tolérance, même efficacité
  3. Itraconazole (gélule ou solution)
  600 mg/j pdt 3 j puis 400 mg/j (dosage J7)
  ! INTERACTION médicamenteuse
  4. Réduire l'immunodépression

TRAITEMENTS ACTUELS

- médicamenteux
- Chirurgie
- Prévention

TRAITEMENTS ACTUELS

Médicaments:

- Voriconazole, Posaconazole
- Formes lipidiques AmB
- Echinocandine

TRAITEMENTS ACTUELS

- **Voriconazole**

  - Plus efficace que l'AmBd
  - Traitement oral et IV
  - IV: dose de charge: - 6mg/kg/12h (2 doses) puis
    - 4mg/kg/12h
  - Per os: dose de charge: - 400 mg/12h (2 doses) puis
    - 200 mg/12h
  - Dosage vallée entre 1 à 5.5 µg/ml
  - Inconvénients: Troubles visuels, adaptation dose si IR ou IH
    interactions médicamenteuses,
    perturbations hépatiques, photosensibilité

Survival Curves for the Modified Intention-to-Treat Population According to Treatment Group

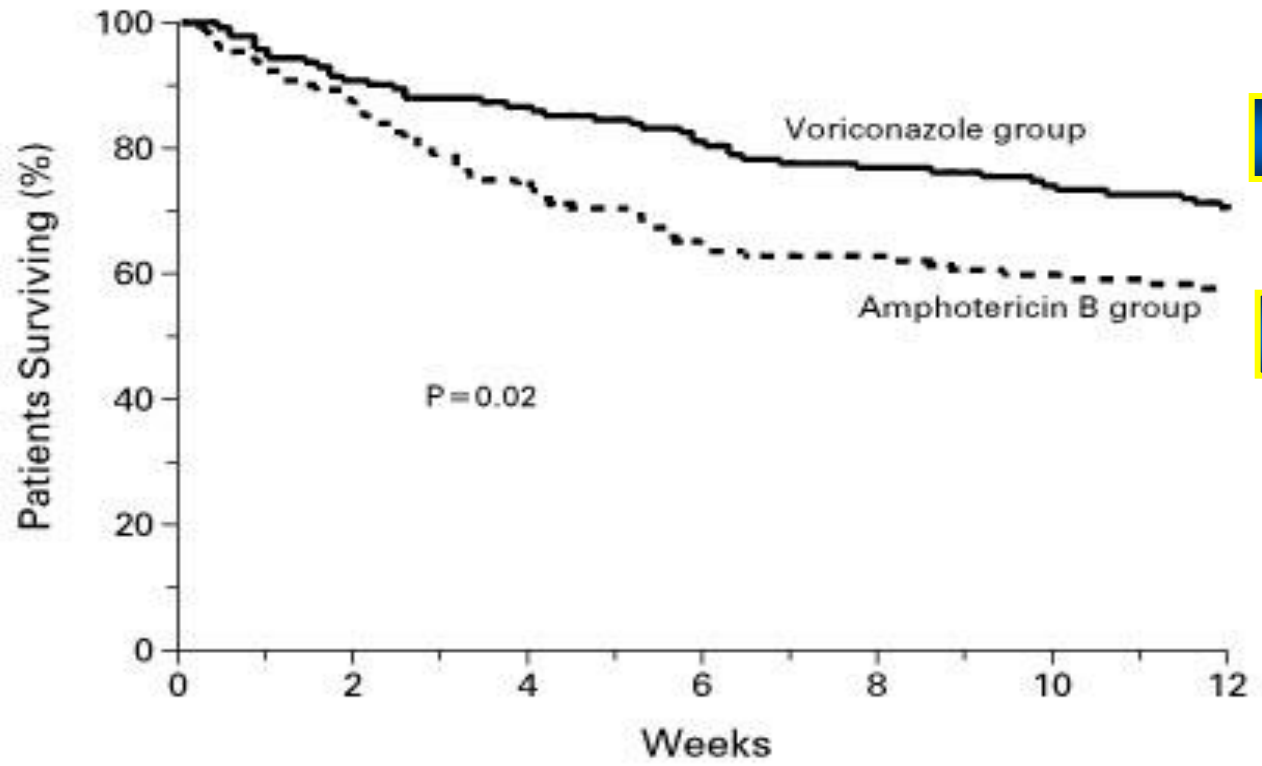

70.8%

57.9%

No. at Risk							
Voriconazole	144	131	125	117	111	107	102
Amphotericin B	133	117	99	87	84	80	77

Herbrecht, R. et al. N Engl J Med 2002;347:408-415

The NEW ENGLAND JOURNAL of MEDICINE

TRAITEMENTS ACTUELS

- **Caspofungine:**

  - Indiqué si intolérance ou échec des autres classes
  - ~ 45% de réponses
  - Très bonne tolérance, peu d'interactions
  - Pas d'adaptation en cas d'IR, âge, sexe, race
  - Voie IV uniquement
  - Dose de charge: 70 mg en 1h puis
  - 50mg/j (évaluer 70mg au besoin)

REMBOURSEMENTS

P/P= proven or probable

Reimbursements		Fungizone	Abelcet	Ambisome	VFend	Noxafil	Cancidas
Immuno-suppression	YES	+	P/P	P/P	P/P	P/P	P/P
	NO	+	-	-	Proven	P/P	-
Renal failure or Intolerance or Refractory	YES	+	< 50	< 25	+	<25	< 25
	NO	+	-	-	+	-	-
	YES	+	+	+	+	+	+
	NO	+	-	-	+	-	-
	YES	+	+	+	+	+	+
	NO	+	-	-	+	-	-
Price (70kg)	Charge	-	-	-	783€(170)	-	615€
	After d1	17€	489€	741€	470€(84)	127€	484€

TRAITEMENTS ACTUELS

Chirurgie: expérience bâloise (Reichenberger, AJRCCM, 1998)

- Période: janvier 83 à décembre 97
- Population: 65 pts atteints d' hémopathie maligne avec API suspectée.
- But: intérêt de l'exérèse chirurgicale ?

TRAITEMENTS ACTUELS

Chirurgie: expérience bâloise (Reichenberger, AJRCCM, 1998)

- Traitement: - chirurgie: 27 pts
  - antifungique : 21/27 (78%)

- Résultats: - API confirmée chez 20 pts
  - complications: 11 pts (2 majeures)
  - mortalité à 3 mois: 23%

CONCLUSION

Diagnostic précoce

⇓

Traitement rapide, y compris chirurgie

Attitude « agressive » : amélioration de la survie

CHU Dinant Godinne
UCL NAMUR

CHU Dinant Godinne
UCL NAMUR





PREVENTION

- Environnement: 1. Isolement des travaux
  2. Isolement du patient:
     - Flux laminaire
     - Chambre à pression +

- Patient: 1. [Amphotéricine B deoxycholate]
  2. Itraconazole/ Voriconazole /Posaconazole
  3. Aérosols AmBd ou Abelcet

PREVENTION

Précautions générales:

- Eviter les plantes naturelles
- Nettoyage physico-chimique
- Eviter les tapis et les aspirateurs, sauf si HEPA
- Stériliser les aliments riches en Aspergillus
- Tabagisme

PREVENTION

Mesures spécifiques:

- Filtres HEPA, 10-12 renouvellements d'air
- Pression positive
- Pression positive et flux laminaire
- Port de masque
- Appareils de stérilisation de l'air?
- Surveillance par prélèvements de l'air?
- Patients à domicile: éviter l'exposition